



+ Evidence in focus

Compendium of clinical evidence

RENASYS[®]

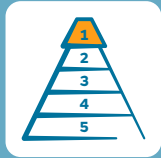Negative Pressure Wound Therapy System

June 2021

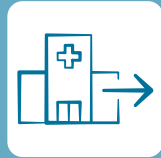Smith+Nephew

Icons and abbreviations

Key for icons



Level of evidence



Outpatient use



Cost analyses

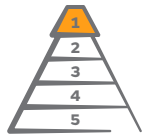

No declared S+N support

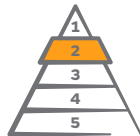

Link to open access reference

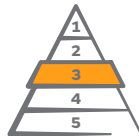Evidence pyramid



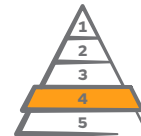Level 1



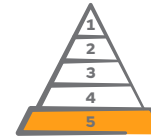Level 2



Level 3



Level 4



Level 5

Abbreviations

ACS	Abdominal compartment syndrome
AI	Adjustable intermittent
CLAP	Continuous local antibiotic perfusion
DFU	Diabetic foot ulcer
DSWI	Deep spinal wound infection
ePTFE	Expanded polytetrafluoroethylene
GP	General practitioner
LD	Latissimus dorsi
MMP	Matrix metalloproteinase

NPWT	Negative pressure wound therapy
NPWTi-d	NPWT with instillation and dwell time
NS	Not significant
STSG	Split thickness skin graft
SWHSI	Surgical wounds healing by secondary intention
tNPWT	Traditional NPWT
TBSA	Total body surface area
VA-ECMO	Veno-arterial extracorporeal membrane oxygenation
VEGF	Vascular endothelial growth factor

RENASYS[◇] tNPWT indications and system features

Intended use and indications

The RENASYS TOUCH and RENASYS GO Systems are indicated for patients who would benefit from a suction device (negative pressure wound therapy), as it may promote wound healing via removal of fluids, including irrigation fluids and body fluids, wound exudate and infectious materials

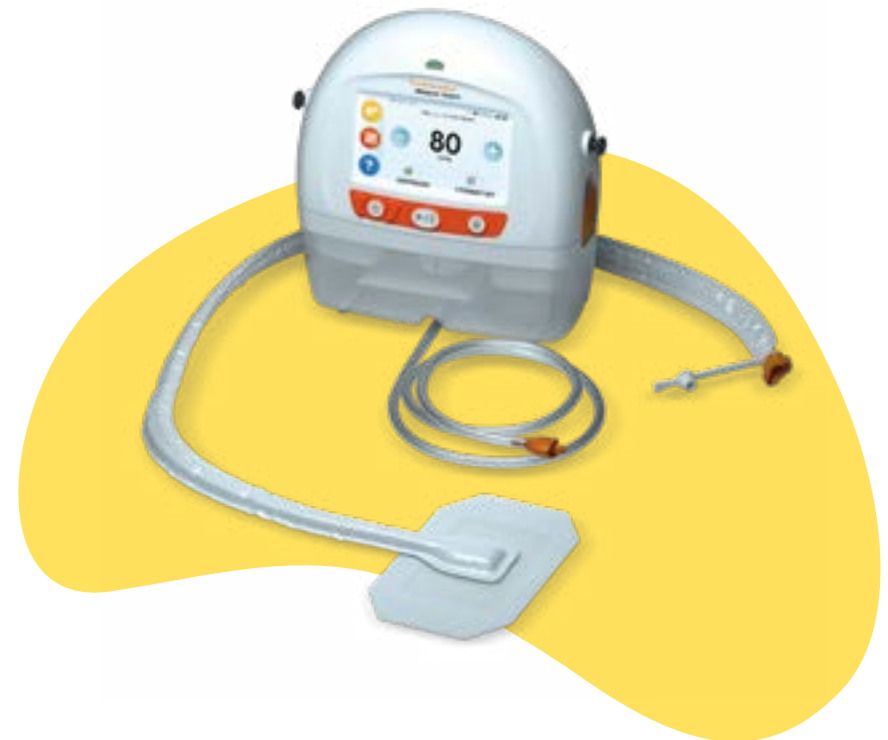Appropriate wound types include:

- Chronic
- Acute
- Traumatic
- Sub-acute and dehisced
- Ulcers (such as pressure or diabetic)
- Partial-thickness burns
- Flaps and grafts

RENASYS tNPWT offers good clinical outcomes across a variety of wound types, similar to those achieved with V.A.C.[™] NPWT (3M KCI, San Antonio, TX, USA)^{1,2}

Furthermore, use of RENASYS TOUCH^{3,4} and Soft Port^{5,6} can help to improve the clinician and patient experience when using NPWT

Aim: This compendium of clinical evidence summarizes published studies about the use of RENASYS tNPWT and provides background information on current practice using NPWT. The compendium also outlines why Smith+Nephew does not provide an instillation NPWT offering.



Inconclusive evidence for use of NPWT with instillation and dwell time (NPWTi-d)

Smith+Nephew does not provide an instillation offering because studies conducted to date do not support a consistent benefit of this treatment approach over conventional NPWT systems, such as RENASYS[®] tNPWT

The EWMA working group publication includes an overview of the principles behind the use of NPWTi-d, the types of wounds for which it is suitable and a review of published studies⁷

It shows how NPWTi-d enables the use of antiseptic and antibiotic solutions for acute and chronic infected wounds, but also highlights a lack of high-quality evidence supporting this approach⁷

Furthermore, clinical guidelines and expert reviews advocate that large randomized controlled trials are needed to determine whether NPWTi-d is more effective than conventional NPWT before it can be recommended for widespread clinical adoption⁸⁻¹²

“Despite its growing popularity, **there is a paucity of evidence and lack of guidance to provide effective use of this therapy [NPWTi-d]**. Available evidence relating to the use of NPWTi-d in acute and chronic wounds is promising but limited in quality, being derived mostly from case series or small retrospective or prospective studies.”

Apelqvist J, et al. 2017¹

Evidence base and challenges using NPWT to help manage acute and chronic wounds

NPWT is an established wound care method that has been in routine clinical use for a range of wound types since the mid to late 1990s⁷

In 2017, the European Wound Management Association (EWMA) published the findings of an interdisciplinary working group that summarized understanding about the use of NPWT⁷

The publication focuses on the implications of using NPWT from the perspective of care organization, documentation, communication, patient safety and health economics⁷

It includes overviews of data supporting the use of conventional NPWT (such as RENASYS[◊] tNPWT) and its modifications including closed incision NPWT (such as PICO[◊] Single Use Negative Pressure Wound Therapy System)⁷

In 2020, an updated overview of current practice using NPWT and the challenges with its use was published¹³

The authors concluded that healthcare professionals, medical directors and procurement have a need for:¹³

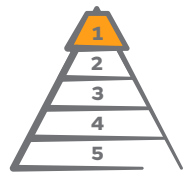- **Evidence-based guidance** on which type of NPWT system to use for different wound types and patient profiles
- **Solutions to address financial and operational inefficiencies with NPWT use**, including reductions in length of hospital stay and improvements to the patient discharge process



Evidence pyramid and topics

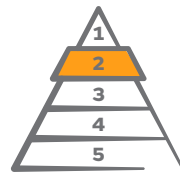In total, **87 clinical publications** that discuss use of RENASYS[◇] tNPWT were identified. The highest levels of evidence available are summarized for each topic; therefore, not all studies are included due to volume of publications.

Levels of evidence



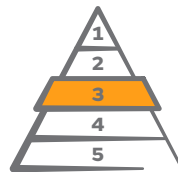9

Randomised controlled trials, systematic reviews and meta-analyses



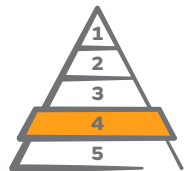5

Prospective, observational comparative studies



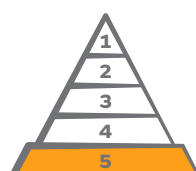8

Retrospective, observational comparative studies



31

Case series (prospective and retrospective)



34

Case reports, letters to the editor, expert opinions

Topic sections

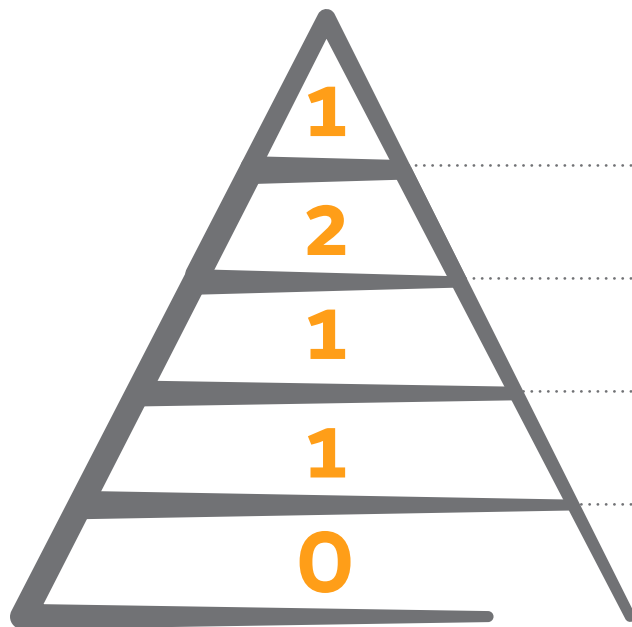
Please select the relevant section to view the key studies that support RENASYS tNPWT use:

Please note that some studies may appear in multiple sections; in sections with high volumes of studies, only those with the highest levels of evidence are included.

RENASYS[◇] tNPWT versus V.A.C.™ NPWT

This section summarizes key studies comparing clinical outcomes using RENASYS tNPWT and V.A.C.™ NPWT. The highest levels of evidence available are summarized; therefore, not all studies are included due to volume of publications.

Evidence pyramid



Randomized controlled trials, systematic reviews and meta-analysis

Prospective, observational comparative studies

Retrospective, observational comparative studies

Case series (prospective and retrospective)

Case reports, letters to the editor, expert opinions

Information correct up to 1 March 2021

Rahmanian-Schwarz A,
et al.



A novel option in negative pressure wound therapy (NPWT) for chronic and acute wound care.

Rahmanian-Schwarz A, Willkomm LM, Gonser P, Hirt B, Schaller HE. *Burns*. 2012;38(4):573–577.

Overview

- A randomized, controlled trial at a single-center in Germany evaluating use of RENASYS GO NPWT (n=20) and V.A.C.™ NPWT (n=22) in patients with acute or chronic wounds
- Foam filler was used with both systems

Results

- No significant differences in clinical outcomes (median values) were noted between RENASYS GO tNPWT and V.A.C.™ NPWT, respectively:
 - Healing time (35.2 vs 37.2 days; Figure)
 - Duration of NPWT application (15.0 vs 13.5 days; p=ns)
 - Number of total and partial dressing changes (3.0 vs 4.2; p=ns)
- Mean costs were lower with RENASYS GO tNPWT than with V.A.C.™ NPWT (11.7% for total cost and 14.0% for cost per day)

Conclusions

RENASYS GO tNPWT was as efficient as V.A.C. NPWT in the management of acute and chronic wounds

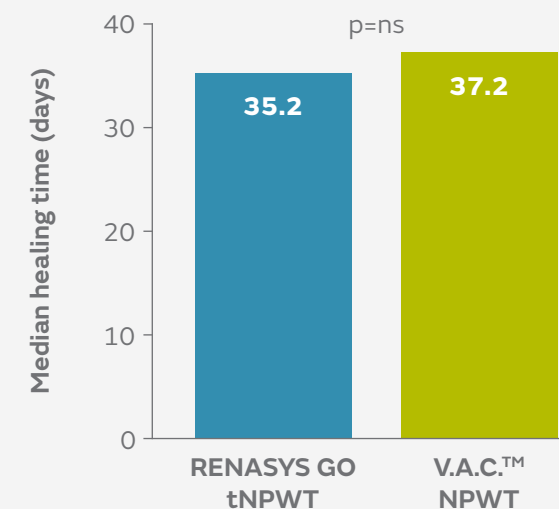


Figure. Median healing time with RENASYS GO tNPWT and V.A.C.™ NPWT in acute and chronic wounds

Fraccalvieri M, et al.



Negative pressure wound therapy using gauze and foam: Histological, immunohistochemical, and ultrasonography morphological analysis of granulation and scar tissues - Second phase of a clinical study.

Fraccalvieri M, Scalise A, Ruka E, et al. *Eur J Plast Surg.* 2014;37(8):411–416.

Overview

- A single-center study evaluating the effects of RENASYS[®] tNPWT with gauze (n=13) and V.A.C.™ NPWT with foam (n=16), on granulation and scar tissue in patients with acute post-trauma wounds
- After 20–25 days of treatment, biopsies of granulation tissue were taken; in a subgroup of patients (n=12) ultrasound analysis was conducted to assess the thickness of newly reconstructed skin

Results

- Using gauze with RENASYS tNPWT compared with foam and V.A.C.™ NPWT, wound healing markers were elevated:
 - VEGF (mean score: 2.0 vs 0.8; p=0.0165)
 - MMPs (mean score: 2.5 vs 1.2)
- Formation of new blood vessels (neovascularisation) increased
- Mean scar depth with RENASYS tNPWT and gauze was smaller than with V.A.C.™ NPWT and foam (7 vs 18mm; 61% relative difference)

Conclusions

Scars of patients with acute post-trauma wounds treated with RENASYS tNPWT and gauze are not as deep as those treated with V.A.C.™ NPWT and foam

Fraccalvieri M, et al.



Patient's pain feedback using negative pressure wound therapy with foam and gauze.

Fraccalvieri M, Ruka E, Bocchiotti MA, Zingarelli E, Bruschi S. *Int Wound J.* 2011;8(5):492–499.

Overview

- A single-center, prospective study comparing pain levels before, during and at dressing change with RENASYS[®] tNPWT and V.A.C.™ NPWT using two different fillers
- Patients with acute trauma wounds received either RENASYS tNPWT with gauze (n=13) or V.A.C.™ NPWT with foam (n=18)
- Patients responded to a questionnaire about pain levels before, during and at dressing change (0, no pain; 10, worst pain imaginable)

Results

- Mean pain scores were lower with RENASYS tNPWT with gauze than with V.A.C.™ NPWT with foam (Figure)
 - During treatment (3.3 vs 4.3)
 - At dressing change (4.2 vs 6.5; p=0.046)

Conclusions

Patients reported significantly less pain at dressing change with use of RENASYS tNPWT with gauze versus V.A.C.™ NPWT with foam

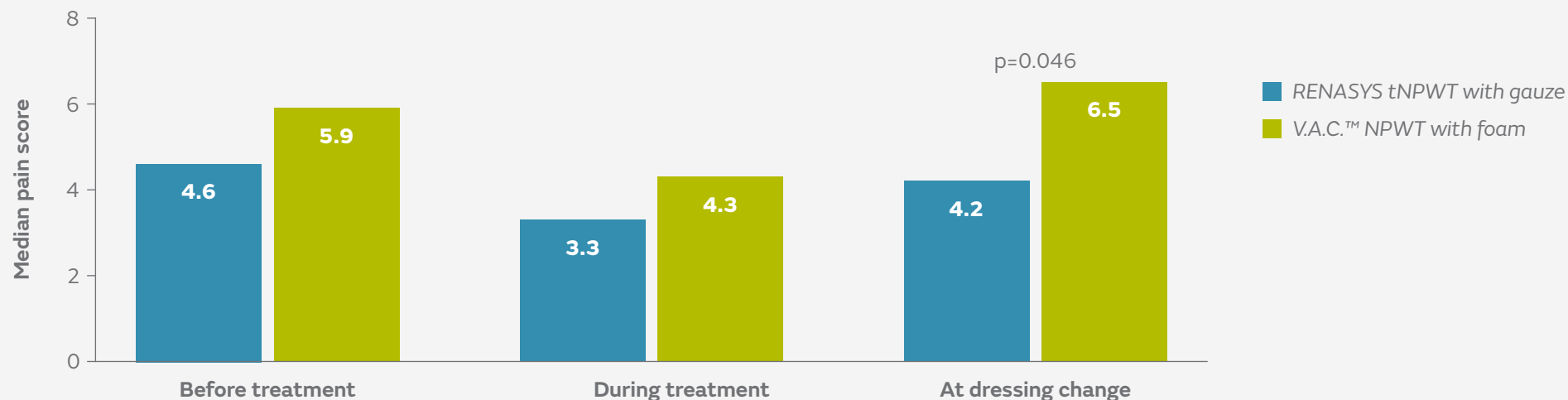
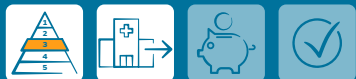

Figure. Mean pain score before treatment, during treatment and during dressing change with RENASYS tNPWT with gauze (n=13) and V.A.C.™ NPWT with foam (n=18)

Hurd T, et al.



A retrospective comparison of the performance of two negative pressure wound therapy systems in the management of wounds of mixed etiology.

Hurd T, Rossington A, Trueman P, Smith J. *Adv Wound Care*. 2017;6(1):33–37.

Overview

- A study comparing clinical outcomes using RENASYS[®] tNPWT with V.A.C.™ NPWT in a community-based setting in Canada
- Patients with a range of wounds (mostly post-surgical) received either RENASYS tNPWT (n=808) or V.A.C.™ NPWT (n=299)

Results

- Similar numbers of patients achieved treatment goal with RENASYS tNPWT and V.A.C.™ NPWT (93.6 vs 90.0%)
- Time taken to achieve treatment goal (median 8 weeks in both groups), mean reduction in wound area (65.3 vs 64.2%), and median weekly reduction in wound area (9.7 vs 9.4%) were also similar in respective groups

Conclusions

There were no differences in clinical outcomes between RENASYS tNPWT and V.A.C.™ NPWT in patients with a range of wounds treated in a community setting

Moffatt C, et al.



The experience of patients with complex wounds and the use of NPWT in a home-care setting.

Moffatt C, Mapplebeck L, Murray S, Morgan P. *J Wound Care*. 2011;20(11):512-527.

Overview

- A study to evaluate the impact of using RENASYS GO tNPWT in a home-care setting
- Patients (n=8) with complex wounds who had received at least 10 days of NPWT were recruited from a tissue viability service in the UK

Results

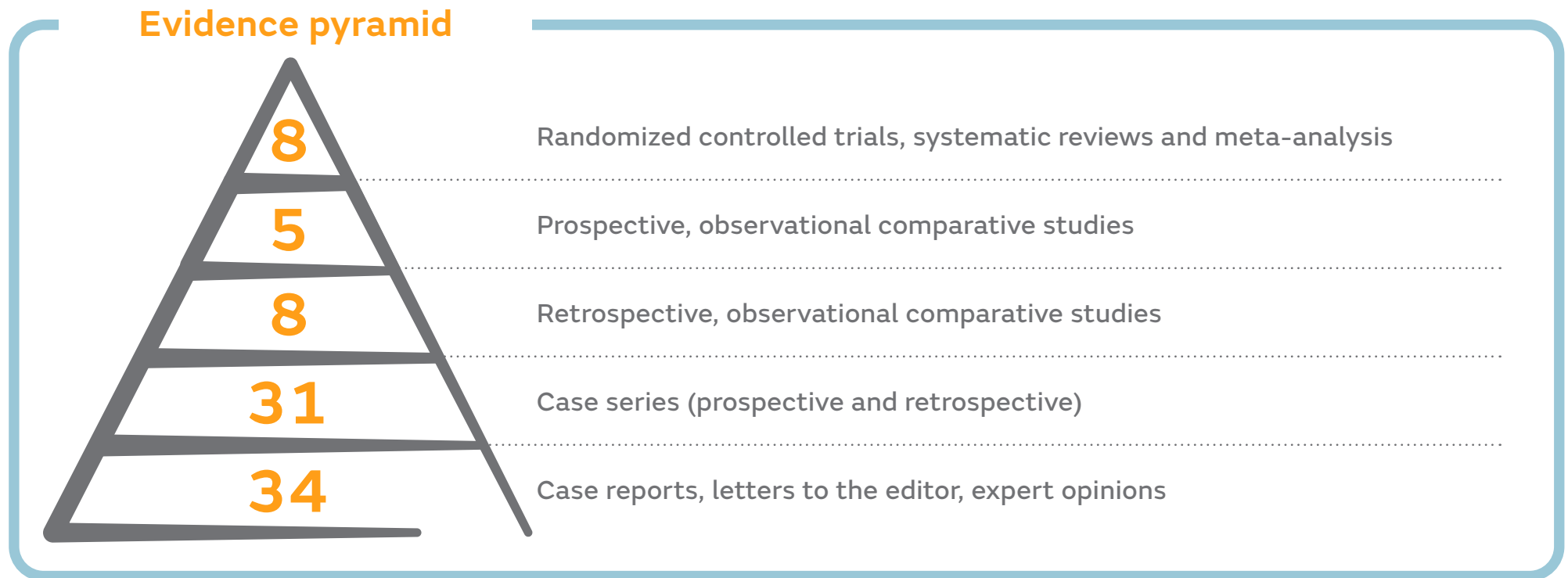- Half of patients achieved wound closure within 2 months

Conclusions

In patients undergoing NPWT for complex wounds in the home-care setting, NPWT was an active intervention that promoted wound healing and symptom control

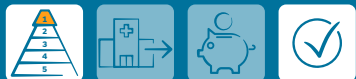Safety and efficacy studies (non-comparative)

This section summarizes key studies evaluating the efficacy and safety of RENASYS[®] tNPWT where there is no comparison with another type of NPWT system. The highest levels of evidence available are summarized; therefore, not all studies are included due to volume of publications.



Information correct up to 1 March 2021

Frear CC, et al.



Randomized clinical trial of negative pressure wound therapy as an adjunctive treatment for small-area thermal burns in children.

Frear CC, Cuttle L, McPhail SM, et al. *Br J Surg.* 2020;107(13):1741–1750.

Overview

- A single-center, randomized controlled trial to compare re-epithelialisation of paediatric burns using a combination of ACTICOAT[◊] Antimicrobial Barrier Dressings and Mepitel[™] wound contact layer (standard dressings) with or without adjunctive RENASYS[◊] TOUCH tNPWT
- Children with thermal burns (TBSA <5%) received either standard dressings (n=54) or standard dressings plus RENASYS TOUCH tNPWT (n=47)

Results

- Median time to re-epithelialisation was 2 days shorter with RENASYS TOUCH tNPWT than with standard dressings (8 vs 10 days; Figure)
- Use of RENASYS TOUCH tNPWT reduced expected time to wound closure by 22% versus standard dressings (p=0.005)
- Risk of referral to scar management was also reduced by 60% with adjunctive NPWT (5 vs 15 patients; p=0.013)
- Fewer patients in the RENASYS TOUCH group underwent grafting than in the standard dressings group (1 vs 4 patients)
- NPWT was discontinued in four patients (wound maceration, periwound blistering and exacerbation of pre-existing viral illnesses); there were no instances of wound infection

Conclusions

Use of RENASYS TOUCH tNPWT in addition to standard dressings resulted in accelerated re-epithelialisation in children with partial-thickness thermal burns and reduced the risk of referral for scar management

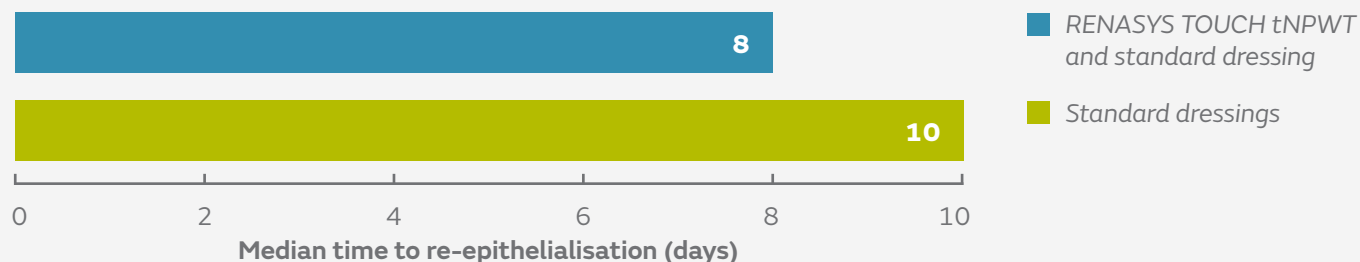
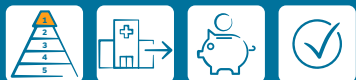

Figure. Median time to re-epithelialisation in paediatric burn patients receiving standard dressings (n=47) and standard dressings plus RENASYS TOUCH tNPWT (n=54)

22% ↓
significant reduction
in time to wound closure
(p=0.005)

Arundel C, et al.



Pilot feasibility randomized clinical trial of negative-pressure wound therapy versus usual care in patients with surgical wounds healing by secondary intention.

Arundel C, Fairhurst C, Corbacho-Martin B, et al. *BJS Open*. 2018;2(3):99–111.

Overview

- A pilot, feasibility, randomized controlled trial for use of NPWT in surgical wounds healing by secondary intention (SWHSI)
- Patients in two acute and one community setting (n=40) in the UK received either NPWT (RENASYS^o tNPWT, V.A.C.TM NPWT or PICO^o sNPWT; n=19) or standard care (n=21) with unspecified dressings
- RENASYS tNPWT was applied in 12 patients, PICO sNPWT in four patients and V.A.C.TM NPWT in one patient

Results

- Wounds of 6 patients in the NPWT group and 4 patients in the standard care group healed within the 3-month study period
- Reductions in wound size and rate of reduction in wound size were similar in both groups
- Patients receiving NPWT reported more hospital care and GP visits, but fewer nurse visits (at surgery or home) in relation to the wound than those in the standard care group (mean total costs €13,096.20 vs €1,591.15)
- Conversely, primary and community care costs were lower with NPWT than with standard care, mostly due to reduced nurse visits
- Two serious adverse events were reported in the NPWT group and three in the standard care group; none were considered to be treatment-related

Conclusions

Use of tNPWT to manage SWHSI is feasible for these often challenging wounds, which can remain open for long periods and require multiple treatment modalities

García AF, et al.



Effect of abdominal negative-pressure wound therapy on the measurement of intra-abdominal pressure.

García AF, Sánchez ÁI, Gutiérrez ÁJ, et al. *J Surg Res.* 2018;227:112–118.

Overview

- A cross-sectional study at a hospital intensive care unit in Colombia
- Intra-abdominal pressure was monitored with and without NPWT in 38 critically ill patients who required temporary abdominal closure
- Where commercially available systems were applied, V.A.C.™ NPWT was used for 27 patients (71.0%), ABThera™ NPWT for 5 patients (13.1%), and RENASYS[®] tNPWT for 2 patients (5.2%)

Results

- Mean intra-abdominal pressure with and without NPWT was 8.33 ± 4.01 mmHg and 8.65 ± 4.04 mmHg, respectively
- There were no statistically significant differences in intra-abdominal pressure measurements with and without NPWT use

Conclusions

Measurement of intra-abdominal pressure, to avoid intra-abdominal hypertension and abdominal compartmental syndrome, in patients with traumatic or nontraumatic surgical emergencies was accurate with and without NPWT

Walker ME, et al.



A prospective, randomized-controlled pilot study comparing closed suction versus negative pressure drains for panniculectomy patients.

Walker ME, Tsay C, Broer PN, et al. *J Plast Reconstr Aesthet Surg.* 2018;71(3):438–439.

Overview

- A prospective, randomized study comparing seroma formation with standard bulb drains versus internal drains attached to continuous negative pressure with RENASYS GO^o tNPWT following panniculectomy
- A total of 34 patients were included; 14 in the RENASYS GO tNPWT group and 20 in the bulb drain group

Results

- Mean drain duration was similar with RENASYS GO tNPWT and bulb drains (14 vs 16 days; p=ns)
- Mean fluid volumes on ultrasound were 14cm³ with RENASYS GO tNPWT and 17cm³ with bulb drains (p=ns)
- On ultrasound, fewer patients treated with RENASYS GO tNPWT had seroma than those who received bulb drains (57 vs 70%; p=ns)
- Incidence of complications was lower with RENASYS GO tNPWT group than with bulb drains (7 vs 35%; p=0.06)

Conclusions

This pilot study suggests that RENASYS GO tNPWT is a safe and viable alternative to bulb drains with no increase in drain duration or wound complications

Forlee M et al.



A randomized controlled trial to compare the clinical efficacy and acceptability of adjustable intermittent and continuous Negative Pressure Wound Therapy (NPWT) in a new portable NPWT system.

Forlee M, van Zyl L, Louw H, Nel J, Fourie N, Hartley R. Poster at the EWMA annual meeting, May 9–11, 2018, Krakow, Poland.

Overview

- An open, prospective, multicenter study conducted in South Africa in patients with acute, sub-acute and chronic wounds that would benefit from RENASYS^o TOUCH tNPWT to achieve adequate wound bed preparation
- Patients received adjustable intermittent (AI; n=35) or continuous therapy (n=36) for 28 days; all settings were determined according to patient need and choice of wound dressing kit and filler were at the investigator's discretion

Results

- Similar proportions of patients achieved readiness for closure in the AI and continuous therapy groups (42.9 vs 44.4%)
- Estimated median reduction from baseline in wound area (7.3 cm²) and volume (11.7 cm³) were both statistically significant (p<0.001; Figure), as was increase in median amount of healthy viable tissue (20.0%; p<0.001)
- By study end, the amount of exudate had reduced significantly from baseline for all patients (p<0.001)
- No pain at dressing application was reported for 65.3% of assessments for AI therapy and 90.6% for continuous therapy
- No pain at dressing removal was reported for 62.7% of assessments for AI therapy and 83.3% for continuous therapy
- Incidence of serious AEs was <10% for all patients and none were device related

Conclusions

RENASYS TOUCH tNPWT was safe and effective at managing all types of wound using both therapeutic modes, with statistically significant decreases in estimated wound area and volume

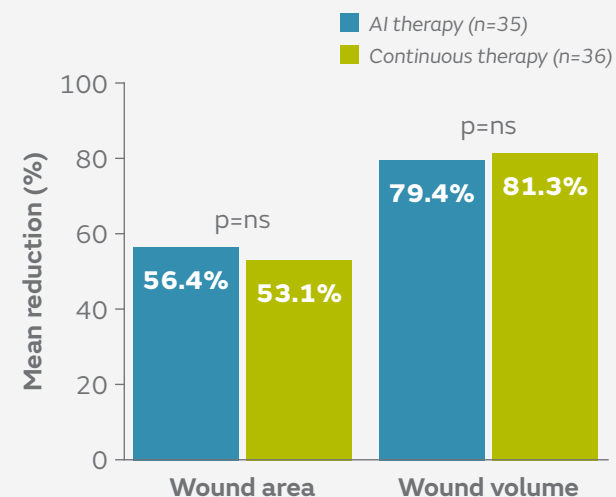


Figure. Mean reductions from baseline in wound area (cm²) and volume (cm³) with AI and continuous therapy (p<0.001 for both)

Angspatt A, et al.



The role of negative-pressure wound therapy in latissimus dorsi flap donor site seroma prevention: a cohort study.

Angspatt A, Laopiyasakul T, Pungrasmi P, Suwajo P. *Arch Plast Surg.* 2017;44(4):308–312.

Overview

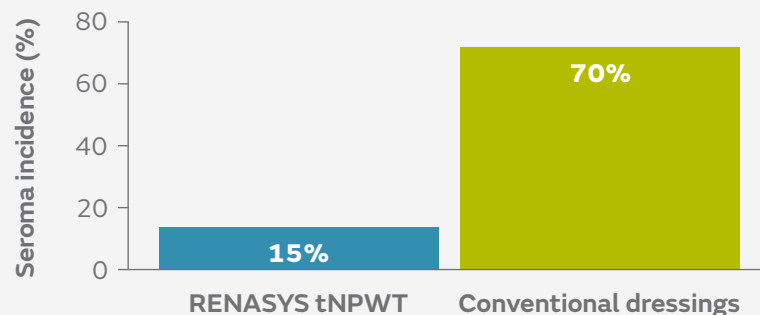
- A prospective, matched-pair study at a single-center in Thailand of 40 patients requiring an LD flap for breast reconstruction
- RENASYS^o tNPWT was used for 20 patients and a conventional donor site dressing (gauze) was used for a further 20 patients
- Postoperative complications (including seroma incidence and drainage volume) were assessed

Results

- Incidence of seroma after drain removal was lower with RENASYS tNPWT than with conventional dressings (15% vs 70%; Figure)
- Mean percutaneous aspirated volume (26 vs 193ml; $p=0.004$) and number of percutaneous aspirations (1 vs 3; $p=0.001$) were significantly lower with RENASYS tNPWT than with conventional dressings
- Total drainage volume and duration of wound drainage were similar in both groups
- Three patients in the NPWT group had minor skin blisters from the adhesive drape that healed spontaneously with conservative treatment; one patient receiving conventional treatment had an infected seroma

Conclusions

Use of RENASYS tNPWT helped to reduce the incidence of seroma after removing the drain at the donor site after LD flap harvesting compared with conventional dressings



55% ↓
reduction in seroma incidence
(odds ratio 0.07)

Figure. Seroma incidence with RENASYS tNPWT and conventional dressings

Sáez-Martín LC, et al.



Negative pressure and nanocrystalline silver dressings for nonhealing ulcer: A randomized pilot study.

Sáez-Martín LC, García-Martínez L, Román-Curto C, Sánchez-Hernández MV, Suárez-Fernández RM. *Wound Rep Regen.* 2015;23(6):948–952.

Overview

- A prospective, randomized pilot study to assess RENASYS^o GO tNPWT and ACTICOAT^o Antimicrobial Barrier Dressings versus RENASYS GO tNPWT alone in the management of chronic wounds at two outpatient clinics in Spain
- Ten patients received the combination treatment and seven patients received RENASYS GO tNPWT alone
- Patients were followed for 6 weeks, with a final assessment at 3 months

Results

- Exudate levels increased to a similar extent throughout the treatment period in both groups
- After 6 weeks, similar amounts of tissue granulation were found in the combination and RENASYS GO tNPWT alone groups (30.0 vs 28.6% of patients)
- Decreases in wound area compared with baseline were similar in both groups
 - In the combination group, there were significant differences versus baseline at week 3 ($p=0.051$) and between weeks 3 and 6 ($p=0.028$)
- No complications or severe adverse events were reported in either group

Conclusions

Use of RENASYS GO tNPWT with ACTICOAT Dressing was safe and as effective as RENASYS tNPWT alone in the management of chronic wounds

Samir AM, Elewa EA.



Safety and efficacy of negative pressure wound therapy in comparison with advanced moist wound therapy in the treatment of diabetic foot ulcers.

Samir AM, Elewa EA. *Egy J Vasc Endovasc Surg.* 2014;10(3):29.

Overview

- A randomized, controlled study by a single-center in Egypt comparing the safety and efficacy of RENASYS^o tNPWT with advanced moist wound care for the management of DFUs in the home-care setting
- Patients received either RENASYS tNPWT using RENASYS-F Foam Dressing Kit with Soft Port (n=57) or advanced moist wound care of hydrogel dressings, calcium alginate and antimicrobial dressings (n=54) for 16 weeks
 - Most patients received offloading (95%)

Results

- With RENASYS tNPWT compared with advanced moist wound care:
 - More patients had complete DFU closure (64.9 vs 44.4%; p=0.03; Figure)
 - Fewer patients required surgical closure by split thickness skin grafts, flaps, sutures or healed by secondary intention (17.5 vs 55%; p=0.003)
 - Duration of therapy was shorter (12.9 vs 14.9 weeks; p=0.007)
 - Fewer patients required amputation (10.5 vs 25.9%; p=0.03) and there were fewer DFU recurrences (1.8 vs 13.0%; p=0.02)

Conclusions

RENASYS tNPWT is as safe as and more efficacious than conventional advanced moist wound care in the management of DFUs used in a home-care setting

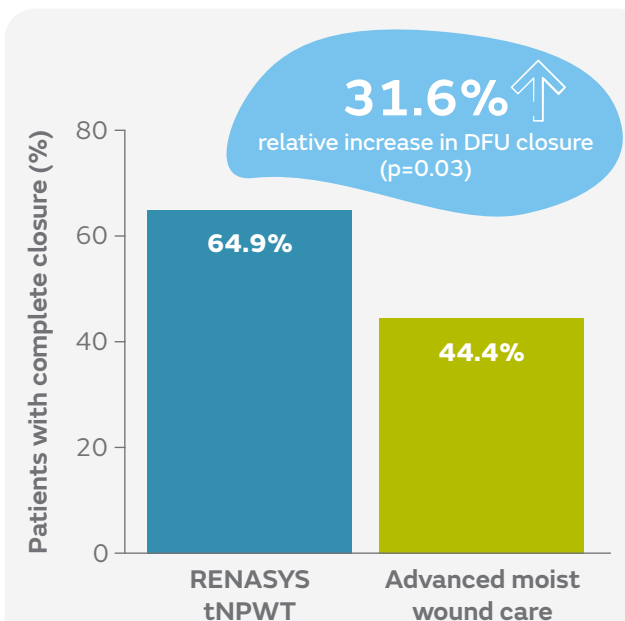


Figure. Patients with complete DFU closure after 16 weeks using RENASYS tNPWT or advanced moist wound care

Kapusta P, et al.



Negative pressure wound therapy affects circulating plasma microRNAs in patients with diabetic foot ulceration.

Kapusta P, Konieczny PS, Hohendorff J, et al. *Diabetes Res Clin Pract.* 2020;165:108251.

Overview

- Patients with DFUs received standard care alone (wounds $\leq 1\text{cm}^2$; n=10) or in addition to RENASYS^o EZ tNPWT with foam filler (wounds $> 1\text{cm}^2$; n=24)

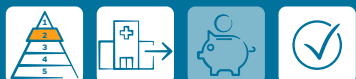Results

- In the RENASYS EZ tNPWT group, there were significant differences in expression of a key modulator of inflammatory responses (let-7f-2-3p miRNA) compared with pre-treatment (p=0.0001), which was not found in the standard care cohort

Conclusions

NPWT might promote wound healing by reducing inflammation and inducing angiogenesis in the wound; miRNA patterns may differ depending on ulcer size

Borys S, et al.



Negative-pressure wound therapy for management of chronic neuropathic noninfected diabetic foot ulcerations—short-term efficacy and long-term outcomes.

Borys S, Hohendorff J, Koblik T, et al. *Endocrine.* 2018;62(3):611–616.

Overview

- A prospective, observational study at a single outpatient clinic in Poland
- Patients with DFUs received standard care alone (wounds $\leq 1\text{ cm}^2$; n=22) or in combination with 8 days of RENASYS EZ tNPWT (wounds $> 1\text{cm}^2$; n=53)

Results

- After 8 days, mean wound area reduced versus baseline in both the RENASYS EZ tNPWT (-1.1 cm^2 , -10.2% ; p=0.0001) and standard care groups (-0.3 cm^2 , -18.0% ; p=0.0038)
- Within 1 year, 55.1% (27/49) of DFUs were closed in the RENASYS EZ tNPWT group and 73.7% (14/19) in the standard care group (p=0.15); recurrence rate was $\sim 30\%$ in both groups

Conclusions

RENASYS EZ tNPWT is a safe treatment for neuropathic, nonischemic, and noninfected DFUs

Schwartz J, et al.



Use of NPWT with and without soft port technology in infected foot wounds undergoing partial diabetic foot amputation.

Schwartz J, Fuller A, Avdagic E, Gendics C, Lantis J. *J Wound Care*. 2015;24(Suppl 9):S4–12.

Overview

- A single-center, prospective study in 29 patients with DFUs treated with RENASYS[®] GO tNPWT and Soft Port (n=9) or an alternative system (n=20), for 112 days, until primary closure, or until the wound was ready for delayed primary closure

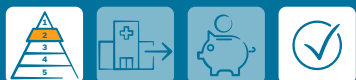Results

- Seven patients (24%) had delayed primary closure (mean, 58 days) and 52% had progressed sufficiently to lead to change in treatment (15/29; mean, 62 days); one DFU had not closed at 112 days
- Median wound area reduced by 39.5% (from 17.4cm² to 7.6cm²; p=0.001) and there were significant reductions in median wound volume and depth (p<0.001)
- RENASYS Soft Port was used for 9 patients and was well tolerated and effective

Conclusions

RENASYS Soft Port was well tolerated and effective; results were comparable with the previous system

Fraccalvieri M, et al.



Patient's pain feedback using negative pressure wound therapy with foam and gauze.

Fraccalvieri M, Ruka E, Bocchiotti MA, Zingarelli E, Bruschi S. *Int Wound J*. 2011;8(5):492–499.

Overview

- A single-center, prospective study comparing pain levels before, during and at dressing change with RENASYS tNPWT and V.A.C.[™] NPWT using two different fillers
- Patients with acute trauma wounds received either RENASYS tNPWT with gauze (n=13) or V.A.C.[™] NPWT with foam (n=18)

Results

- Mean pain scores were lower with RENASYS tNPWT with gauze than V.A.C.[™] NPWT with foam (0, no pain; 10, worst pain imaginable)
 - During treatment (3.3 vs 4.3)
 - At dressing change (4.2 vs 6.5; p=0.046)

Conclusions

Patients reported significantly less pain at dressing change with use of RENASYS tNPWT with gauze versus V.A.C.[™] NPWT with foam

Fraccalvieri M, et al.



Negative pressure wound therapy using gauze and foam: Histological, immunohistochemical, and ultrasonography morphological analysis of granulation and scar tissues - Second phase of a clinical study.

Fraccalvieri M, Scalise A, Ruka E, et al. *Eur J Plast Surg.* 2014;37(8):411–416.

Overview

- A single-center study evaluating the effects of RENASYS[®] tNPWT with gauze (n=13) and V.A.C.[™] NPWT with foam (n=16), on granulation and scar tissue in patients with acute post-trauma wounds
- After 20–25 days of treatment, biopsies of granulation tissue were taken; in a subgroup of patients (n=12) ultrasound analysis was conducted to assess the thickness of newly reconstructed skin

Results

- Using RENASYS tNPWT with gauze compared with V.A.C.[™] NPWT and foam, wound healing markers were elevated:
 - VEGF (mean score: 2.0 vs 0.8; p=0.0165)
 - MMPs (mean score: 2.5 vs 1.2)
- Formation of new blood vessels (neovascularisation) increased
- Mean scar depth with RENASYS tNPWT and gauze was smaller than with V.A.C.[™] NPWT and foam (7 vs 18mm; 61% relative difference)

Conclusions

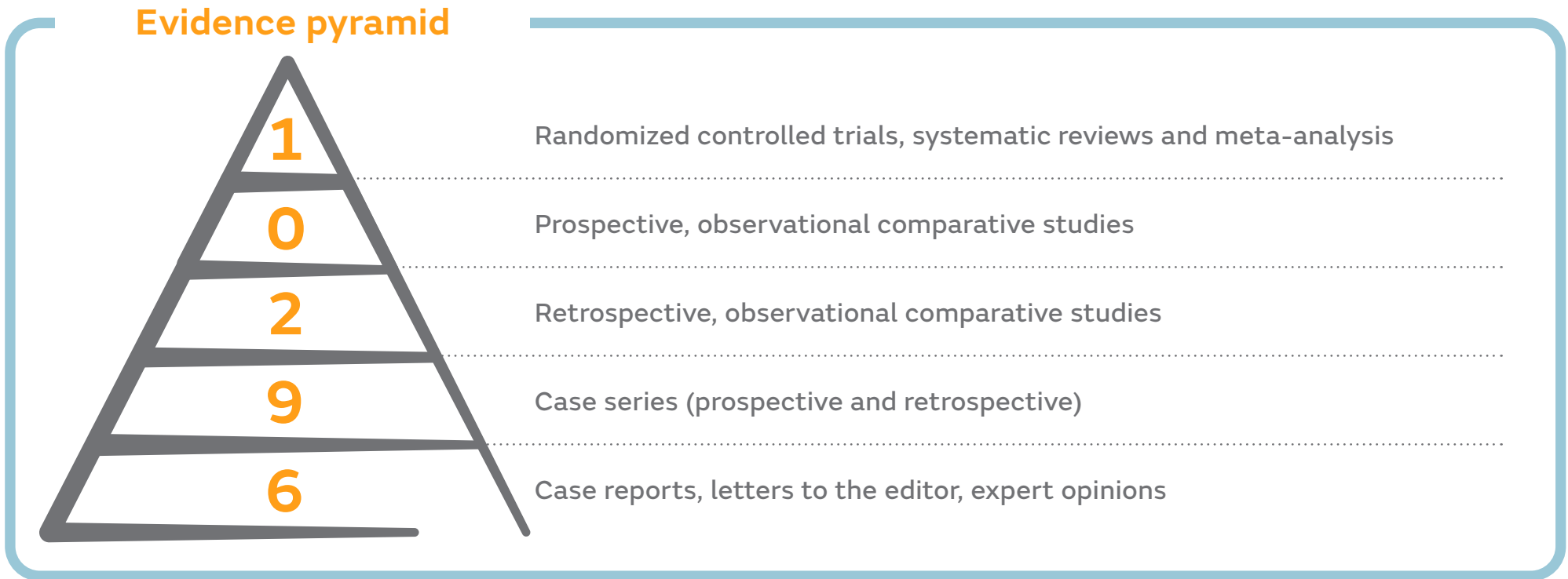Scars of patients with acute post-trauma wounds treated with RENASYS tNPWT and gauze are not as deep as those treated with V.A.C.[™] NPWT and foam

Additional supporting studies

<p>Hasaballah A, Aboloyoun H, Elbadawy A, Ezeldeen M. <i>Egyptian J Surg.</i> 2019;38(1):165.</p>	<p>Impact of negative pressure wound therapy in complete healing rates following surgical debridement in heel and ankle regions in diabetic foot infections.</p>	   
<p>Matsumine H, Fujimaki H, Takagi M, et al. <i>Regen Ther.</i> 2019;11:81–87.</p>	<p>Full-thickness skin reconstruction with basic fibroblast growth factor-impregnated collagen-gelatin sponge.</p>	   
<p>Nakamura Y, Fujisawa Y, Ishitsuka Y, et al. <i>J Dermatol.</i> 2018;45(10):1207–1210.</p>	<p>Negative-pressure closure was superior to tie-over technique for stabilization of split-thickness skin graft in large or muscle-exposing defects: A retrospective study.</p>	    
<p>Hurd T, Rossington A, Trueman P, Smith J. <i>Adv Wound Care.</i> 2017;6(1):33–37.</p>	<p>A retrospective comparison of the performance of two negative pressure wound therapy systems in the management of wounds of mixed etiology.</p>	   
<p>Hattori K, Numanoglu A, Cox S. <i>Eur J Pediatr Surg.</i> 2017;27(5):437–442.</p>	<p>Temporary vacuum-assisted closure of the open abdomen in neonates.</p>	    
<p>Krebs B, Jagric T. <i>Adv Skin Wound Care.</i> 2017;30(6):256–261.</p>	<p>Does negative-pressure wound therapy for the open abdomen benefit the patient? A retrospective cohort study.</p>	    
<p>Matsuzaki K, Kishi K. <i>Eur J Plastic Surg.</i> 2016;39(5):353–358.</p>	<p>Negative-pressure wound therapy for diabetic ischemic foot wounds in hemodialysis patients.</p>	    
<p>Todd J, Ud-Din S, Bayat A. <i>Eplasty.</i> 2012;12:e23.</p>	<p>Extensive self-harm scarring: successful treatment with simultaneous use of a single layer skin substitute and split-thickness skin graft.</p>	   

Abdominal wound studies with RENASYS[◇] tNPWT

This section summarizes key studies evaluating the efficacy and safety of RENASYS tNPWT in patients with abdominal wounds. The highest levels of evidence available are summarized; therefore, not all studies are included due to volume of publications.



Information correct up to 1 March 2021

García AF, et al.



Effect of abdominal negative-pressure wound therapy on the measurement of intra-abdominal pressure.

García AF, Sánchez ÁI, Gutiérrez ÁJ, et al. *J Surg Res.* 2018;227:112–118.

Overview

- A cross-sectional study at a hospital intensive care unit in Colombia
- Intra-abdominal pressure was monitored with and without NPWT in 38 critically ill patients who required temporary abdominal closure
- Where commercially available systems were applied, V.A.C.™ NPWT was used for 27 patients (71.0%), ABThera™ NPWT for 5 patients (13.1%), and RENASYS[®] tNPWT for 2 patients (5.2%)

Results

- Mean intra-abdominal pressure with and without NPWT was 8.33 ± 4.01 mmHg and 8.65 ± 4.04 mmHg, respectively
- There were no statistically significant differences in intra-abdominal pressure measurements with and without NPWT use

Conclusions

Measurement of intra-abdominal pressure, to avoid intra-abdominal hypertension and abdominal compartmental syndrome, in patients with traumatic or nontraumatic surgical emergencies was accurate with and without NPWT

Hattori K, et al.



Temporary vacuum-assisted closure of the open abdomen in neonates.

Hattori K, Numanoglu A, Cox S. *Eur J Pediatr Surg.* 2017;27(5):437–442.

Overview

- A retrospective review of neonates treated with RENASYS[®] EZ PLUS tNPWT with RENASYS Soft Port and foam filler for open abdomen between 2010 to 2014 at a centre in South Africa
- A total of 15 neonates received temporary closure for confirmed ACS (n=2) and to help prevent ACS (n=13)

Results

- Duration of RENASYS tNPWT use was 4 ± 3.4 days, during which 2 ± 1.2 applications were performed
- Overall survival rate was 80% (12 of 15 patients)
- One patient with primary ACS died from sepsis with an open abdomen

Conclusions

Use of RENASYS tNPWT on the open abdomen is a safe method of temporary abdominal closure to help prevent ACS in high-risk postoperative conditions in neonates of any gestational age and birth weight

Krebs B, Jagric T.



Does negative-pressure wound therapy for the open abdomen benefit the patient? A retrospective cohort study.

Krebs B, Jagric T. *Adv Skin Wound Care.* 2017;30(6):256–261.

Overview

- A retrospective, single-center cohort study in Slovenia using a prospective database of all patients treated with RENASYS-AB Abdominal Dressing Kit (January 2011 to December 2014) to identify risk factors for mortality
- A total of 27 patients were treated after an elective operation with complications, and 25 after emergency surgery (usually peritonitis after perforation of the bowel)

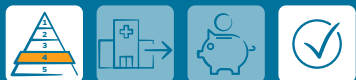Results

- Mean number of RENASYS tNPWT changes before closing was 4
- Type of wound closure, >7 RENASYS tNPWT dressing changes, and longer time to wound closure, were significantly associated with death
- Number of surgeries before application of RENASYS tNPWT did not affect postoperative survival

Conclusions

In this study, use of RENASYS tNPWT was effective for treating the open abdomen when applied quickly and where appropriately indicated

Inukai K, et al.



Open abdominal management for perforative peritonitis with septic shock: a retrospective analysis on usefulness of a standardized treatment protocol.

Inukai K, Usui A, Yamada M, et al. *Eur J Trauma Emerg Surg.* 2021;47(1):93–98.

Overview

- A retrospective review of 25 critically ill patients requiring open abdominal management with RENASYS[®] tNPWT or V.A.C.[™] NPWT (Jun 2015 to Sep 2018) at a single-center in Japan

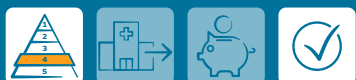Results

- Mortality was 4% (1 of 25 patients); overall morbidity of surviving patients was 58.3% (14 of 24 patients)
- Mean duration of the first damage control surgery was 67±23min; median duration of ventilation and ICU stay were 5 and 7 days, respectively

Conclusions

Management of open abdomen with NPWT is viable for perforative peritonitis and septic shock

Morais M, et al.



The open abdomen: analysis of risk factors for mortality and delayed fascial closure in 101 patients.

Morais M, Gonçalves D, Bessa-Melo R, Devesa V, Costa-Maia J. *Porto Biomedical Journal.* 2018;3(2):e14.

Overview

- A retrospective analysis of 89 patients who underwent open abdomen management (63 with RENASYS tNPWT, 26 with the Barker technique) for acute abdominal conditions (Jan 2009 to Mar 2017) at a single-center in Portugal

Results

- Overall mortality was 62.4%; 28 of 37 patients discharged from the hospital had definitive abdominal closure
- Patients aged >60 years, and with APACHE II scores >18.5, had high in-hospital mortality

Conclusions

Open abdomen management with RENASYS tNPWT may be appropriate in critically ill patients; however, it can be associated with high mortality, especially in elderly patients and with high APACHE II scores

Robin-Lersundi A, et al.



Temporary abdominal closure with polytetrafluoroethylene prosthetic mesh in critically ill non-trauma patients.

Robin-Lersundi A, Ruiz VV, López-Monclús J, et al. *Hernia*. 2015;19(2):329–337.

Overview

- A study of 29 critically ill non-trauma patients who underwent temporary abdominal closure with ePTFE mesh (plus RENASYS[®] tNPWT for drainage in 14 patients) due to sepsis or ACS at two hospitals in Spain

Results

- 16 of 29 patients (69.5%) survived temporary abdominal closure and went on to have definitive abdominal wall closure

Conclusions

RENASYS tNPWT was successfully used in combination with ePTFE mesh for temporary abdominal closure

Di Saverio S, et al.



Open abdomen with concomitant enteroatmospheric fistula: attempt to rationalize the approach to a surgical nightmare and proposal of a clinical algorithm.

Di Saverio S, Tarasconi A, Inaba K, et al. *J Am Coll Surg*. 2015;220(3):e23–33.

Overview

- Evaluation of RENASYS tNPWT as part of algorithm development for patients with open abdomen and concomitant enteroatmospheric fistula

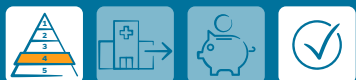Results

- Use of baby bottle nipple diversion approach using RENASYS tNPWT diverted fistula output where multiple fistulas were present
- This approach also promoted granulation formation over exposed bowel

Conclusions

Use of baby bottle nipple diversion with RENASYS tNPWT successfully diverted fistula output to help control sepsis

Timmons J, Russell F.



The use of negative-pressure wound therapy to manage enteroatmospheric fistula in two patients with large abdominal wounds.

Timmons J, Russell F. *Int Wound J.* 2014;11(6):723–729.

Overview

- Two patient cases using RENASYS^o GO tNPWT (one with gauze and one with foam filler) to help manage open abdominal wounds with fistulae

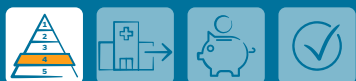Results

- RENASYS GO tNPWT dressing was changed every 3 days; patients were mobile and were confident to conduct activities of daily living without the dressing coming off
- Both wounds granulated

Conclusions

RENASYS GO tNPWT was successfully applied for managing open abdomen wounds with fistulae after major abdominal surgery

Navsaria P, et al.



Negative pressure wound therapy management of the "open abdomen" following trauma: a prospective study and systematic review.

Navsaria P, Nicol A, Hudson D, Cockwill J, Smith J. *WJES.* 2013;8(1):4.

Overview

- A prospective open-label, non-comparative study of 20 trauma patients requiring temporary abdominal closure with RENASYS EZ tNPWT

Results

- Fascial closure was achieved in 13 out of 20 patients
- One patient died; the remaining 12 with closed abdomens were stable at a follow up 8 days after closure
- Median time to achieve primary fascial closure was 3 days

Conclusions

Use of RENASYS EZ tNPWT was safe and effective, resulting in a high rate of fascial closure rate in severely injured trauma patients

De Martino C, et al.



Laparostomy with topical negative pressure for treating severe peritonitis: Preliminary experience with 16 cases and review of the literature.

De Martino C, Caiazzo P, Albano M, Calbi F, Pastore M, Tramutoli PR. *Ann Ital Chir.* 2013;84(4):429–436.

Overview

- Case series (n=16) from a single-center in Italy of patients who underwent emergency laparotomy and laparostomy formation using RENASYS[®] tNPWT for severe peritonitis

Results

- Overall mortality was 31.5% (5/16 patients); two patients died before abdominal closure
- At follow-up 6 patients (37.5%) were completely healed; two patients (12.5%) developed a laparocoele

Conclusions

Use of RENASYS tNPWT with laparostomy for the management of severe peritonitis was safe and effective compared with validated techniques

Choi WW, et al.



Negative pressure wound therapy in the management of neonates with complex gastroschisis.

Choi WW, McBride CA, Kimble RM. *Pediatr Surg Int.* 2011;27(8):907–911.

Overview

- Case series (n=4) from a single-center in Australia of neonatal patients with complex gastritis receiving RENASYS tNPWT with RENASYS-G Gauze Dressing Kit with Soft Port to help prevent respiratory embarrassment and/or abdominal compartment syndrome

Results

- All patients achieved closure of their gastroschisis defects

Conclusions

Use of RENASYS tNPWT was safe and effective in all four neonates with complex gastroschisis for whom the size of the defect and the condition of the bowel and/or neonate precluded primary closure of the abdomen

Giungato S, Pepe AS.



Use of negative pressure therapy for extreme patients refractory to conventional therapies and surgical procedures.

Giungato S, Pepe AS. *Surg Endosc.* 2018;32:S483–S614. (P043)

Overview

- A study of 13 patients with cutaneous ulcers refractory to advanced medications, laparotomy dehiscence and post incisional muscular wall defects, one of whom was treated with RENASYS[®]-AB and GORE™ BIO-A™ prosthesis

Results

- The patient's wound healed after 4 months without bowel fistula formation

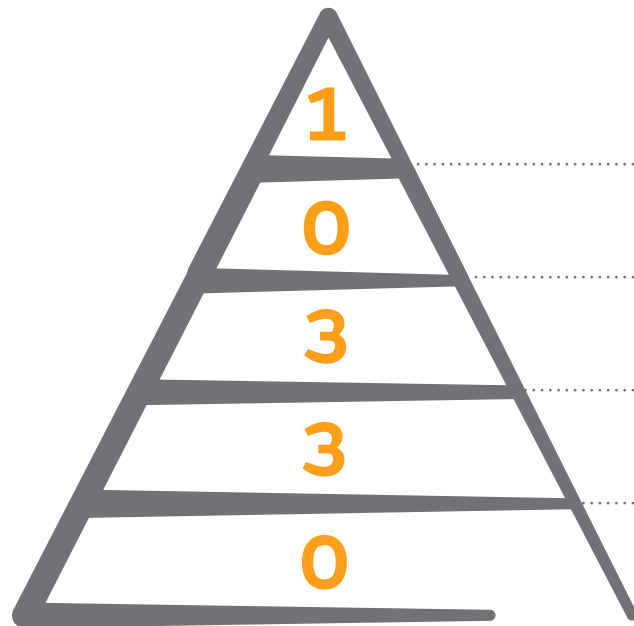
Conclusions

Use of GORE™ BIO-A™ prosthesis with RENASYS-AB was feasible, simple and successful

Intermittent use of RENASYS[◇] tNPWT

This section summarizes key studies evaluating the intermittent delivery of NPWT using RENASYS tNPWT rather than continuous delivery of NPWT. The highest levels of evidence available are summarized; therefore, not all studies are included due to volume of publications.

Evidence pyramid



Randomized controlled trials, systematic reviews and meta-analysis

Prospective, observational comparative studies

Retrospective, observational comparative studies

Case series (prospective and retrospective)

Case reports, letters to the editor, expert opinions

Information correct up to 1 March 2021

Forlee M, et al.



A randomized controlled trial to compare the clinical efficacy and acceptability of adjustable intermittent and continuous Negative Pressure Wound Therapy (NPWT) in a new portable NPWT system.

Forlee M, van Zyl L, Louw H, Nel J, Fourie N, Hartley R. Poster at the EWMA annual meeting, May 9–11, 2018, Krakow, Poland.

Overview

- An open, prospective, multi-center study conducted in South Africa in patients with acute, sub-acute and chronic wounds that would benefit from RENASYS[®] TOUCH tNPWT to achieve adequate wound bed preparation
- Patients received adjustable intermittent (AI; n=35) or continuous therapy (n=36) for 28 days; all settings were determined according to patient need, and choice of wound dressing kit and filler were at the investigator's discretion

Results

- Similar proportions of patients achieved readiness for closure in the AI and continuous therapy groups (42.9 vs 44.4%)
- For intermittent NPWT the most frequently selected cycle time was '10min on' and '2min off'
- Estimated median reduction from baseline in wound area (7.3 cm²) and volume (11.7 cm³) were both statistically significant (p<0.001; Figure), as was increase in median amount of healthy viable tissue (20.0%; p<0.001)
- By study end the amount of exudate had reduced significantly for all patients (p<0.001)
- No pain at dressing application was reported for 65.3% of assessments for AI therapy and 90.6% for continuous therapy
- No pain at dressing removal was reported for 62.7% of assessments for AI therapy and 83.3% for continuous therapy
- Both therapy modes were comfortable to wear at >99% of dressing changes
- Clinician acceptability of device functionality was >90% for all parameters assessed using either mode

Conclusions

RENASYS TOUCH tNPWT was effective at managing all types of wound using both therapeutic modes with statistically significant decreases in estimated wound area and volume

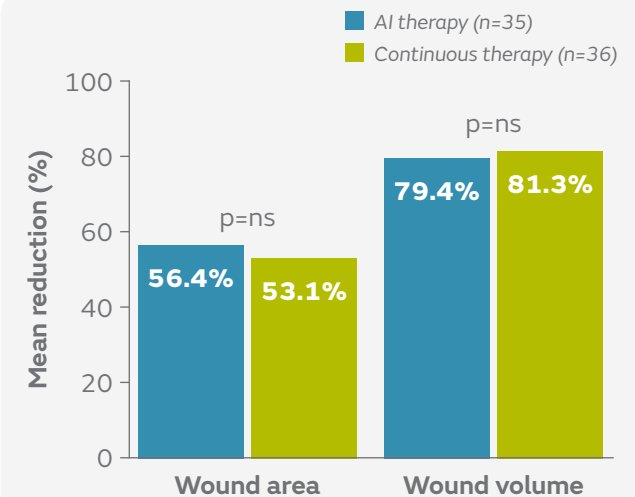
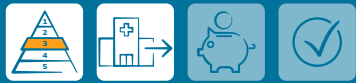

Figure. Mean reductions from baseline in wound area (cm²) and volume (cm³) with AI and continuous therapy (p<0.001 for both)

Hurd T, et al.



A retrospective comparison of the performance of two negative pressure wound therapy systems in the management of wounds of mixed etiology.

Hurd T, Rossington A, Trueman P, Smith J. *Adv Wound Care*. 2017;6(1):33–37.

Overview

- A study comparing clinical outcomes using RENASYS[®] tNPWT with V.A.C.[™] NPWT in a community based setting in Canada
- Patients with a range of wounds (mostly post-surgical wounds) received either RENASYS tNPWT (n=808) or V.A.C.[™] NPWT (n=299)
- For wounds with large fluid volumes, after 2 weeks of therapy with continuous NPWT and once drainage was controlled, intermittent NPWT was then applied for the remainder of the therapy (6% of patients)
- For wounds with suspected localized bacterial burden or infection ACTICOAT[®] FLEX 3 Antimicrobial Barrier Dressing was applied according to local protocols (34%)

Results

- Similar numbers of patients achieved treatment goal with RENASYS tNPWT and V.A.C.[™] NPWT (93.6 vs 90.0%)
- Time taken to achieve treatment goal (median 8 weeks in both groups; Figure), mean reduction in wound area (65.3 vs 64.2%; Figure), and median weekly reduction in wound area (9.7 vs 9.4%) were also similar
- ACTICOAT FLEX 3 Dressing was used successfully as an adjunct to either NPWT system

Conclusions

There were no differences in clinical outcomes between RENASYS tNPWT and V.A.C.[™] NPWT (continuous and intermittent use) in patients with a range of wounds treated in a community setting

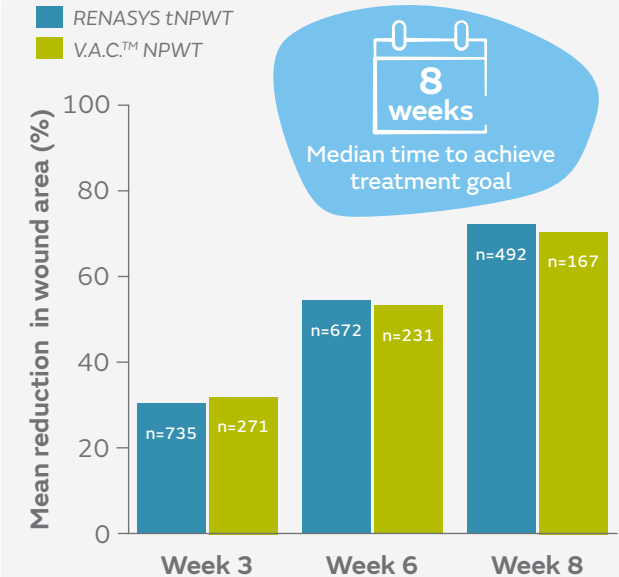
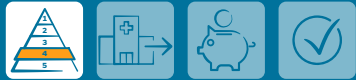

Figure. Mean reductions in wound area during treatment with RENASYS tNPWT (n=808) and V.A.C.[™] NPWT (n=299)

Intermittent use

Forlee M.



Retrospective chronic and post-surgical wound case series: Understanding RENASYS[®] TOUCH.

Forlee M. *Wounds International*. 6 Jan 2020:1–12.

Overview

- A series of eight patient cases treated with RENASYS TOUCH tNPWT as part of an open-label, multi-center, randomized controlled trial conducted in South Africa
- Two cases required intermittent use RENASYS TOUCH tNPWT to help manage pain and infection, respectively

Results

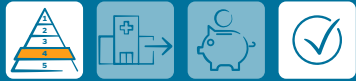- **Patient 1** – a lower extremity, sub-acute wound arising from a postsurgical wound
- NPWT was applied in adjustable intermittent mode for the first 14 days and was well tolerated, with good wound progression
- At ~14 days, intermittent therapy was changed to continuous therapy to minimize wound pain for the rest of treatment
- ACTICOAT[®] FLEX 3 Dressing was applied to manage signs of infection
- At end of therapy there were wound reductions of 100% in depth and 58.5% in area
- **Patient 2** – a post-surgical wound on the heel with partial dehiscence (signs of infection, necrosis and periwound skin inflammation)
- ACTICOAT FLEX 3 Dressing was applied under RENASYS-F foam filler and adjustable intermittent pressure was applied at –120mmHg (10min), then –25mmHg (2min)
- All signs of clinical infection had resolved by day 16 and at day 28, the wound had reduced in area by 88.5% and volume by 40.0%
- **Patient 3** – a painful venous leg ulcer (4 weeks in duration)
- RENASYS-F was applied using the adjustable intermittent mode with set points of –120 mmHg (10min) to –25 mmHg (2min), later reduced to –80 mmHg and –25 mmHg due to pain
- After 16 days, wound area reduction was 55.6%, wound depth was 0mm, and wound volume had also reduced

Conclusions

The ability to adapt therapy with RENASYS GO tNPWT gave the clinician options with regard to patient tolerability of NPWT; use of RENASYS GO tNPWT resulted in progress towards closure in all cases

Intermittent use

Vaseenon T, Somsuk W.



Negative pressure wound therapy for traumatic foot and ankle wound: two case reports and review of the literature.

Vaseenon T, Somsuk W. *J Med Assoc Thai.* 2015;98(1):111–116.

Overview

- Two case reports from a single-center in Thailand of patients who presented with open soft tissue injuries and Achilles tendon tears at the posterior ankle and heel that required treatment with RENASYS[◊] GO tNPWT
- Negative pressure with RENASYS GO tNPWT was delivered using intermittent mode at –80mmHg for both patients (with foam filler)
 - **Patient 1** also received INTRASITE[◊] GEL Hydrogel Wound Dressing
 - **Patient 2** also received ACTICOAT[◊] Antimicrobial Barrier Dressing

Results

- **Patient 1** – after 2 weeks of using RENASYS GO tNPWT, wound size decreased and granulation tissue covered the Achilles tendon
- Two weeks after the operation, the patient was discharged from hospital
- **Patient 2** – 7 days after the initial treatment using RENASYS GO tNPWT in intermittent mode, exposed bone and Achilles tendon were completely covered with granulation tissue
- RENASYS GO tNPWT was then used continuously for another 7 days to promote granulation tissue for further skin coverage
- Eight weeks after surgical debridement, the wound was completely filled with granulation tissue and had decreased in size, so split thickness skin grafting was carried out

Conclusions

Use of RENASYS GO tNPWT in intermittent mode was an effective adjunct treatment option for managing these two cases of complex wounds where reconstructive surgery with skin flaps was not possible

Intermittent use

De Martino C, et al.



Laparostomy with topical negative pressure for treating severe peritonitis: Preliminary experience with 16 cases and review of the literature.

De Martino C, Caiazzo P, Albano M, Calbi F, Pastore M, Tramutoli PR. *Ann Ital Chir.* 2013;84(4):429–436.

Overview

- Case series (n=16) from a single-center in Italy of patients who underwent emergency laparotomy and laparostomy formation using RENASYS[®] tNPWT for severe peritonitis
- Negative pressure was delivered intermittently at 50–80mmHg, depending on the amount of abdominal secretions (greater pressure) and bleeding (lesser pressure)

Results

- Overall mortality was 31.5% (5/16 patients); two patients died before abdominal closure
- At follow-up 6 patients (37.5%) were completely healed; two patients (12.5%) developed a laparocele

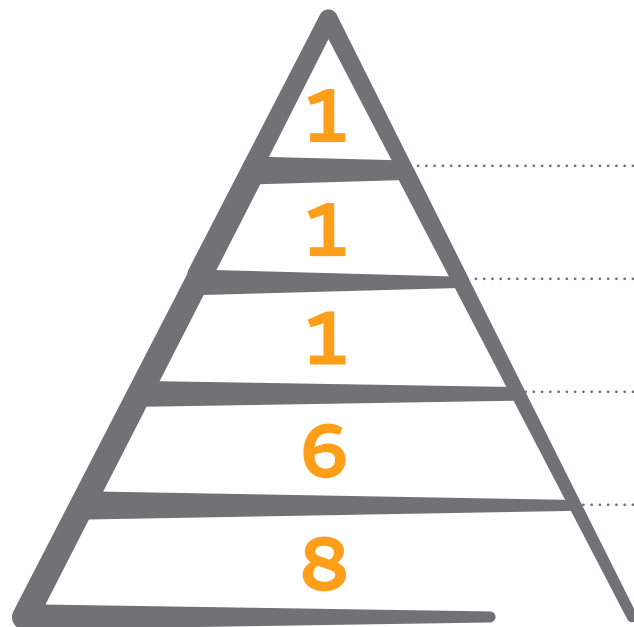
Conclusions

Use of RENASYS tNPWT in intermittent mode with laparostomy for the management of severe peritonitis was safe and effective when compared to validated techniques

Use of RENASYS[◇]-G and RENASYS-F Dressing kits

This section summarizes key studies evaluating the use of RENASYS-G Dressing Kit with Soft Port and RENASYS-F Dressing Kit with Soft Port. The highest levels of evidence available are summarized; therefore, not all studies are included due to volume of publications.

Evidence pyramid



Randomized controlled trials, systematic reviews and meta-analysis

Prospective, observational comparative studies

Retrospective, observational comparative studies

Case series (prospective and retrospective)

Case reports, letters to the editor, expert opinions

Information correct up to 1 March 2021

Samir AM, Elewa EA.



Safety and efficacy of negative pressure wound therapy in comparison with advanced moist wound therapy in the treatment of diabetic foot ulcers.

Samir AM, Elewa EA. *Egy J Vasc Endovasc Surg.* 2014;10(3):29.

Overview

- A randomized, controlled study by a single-center in Egypt comparing the safety and efficacy of RENASYS[◊] tNPWT with advanced moist wound care for the management of DFUs in the home-care setting
- Patients received either RENASYS tNPWT using RENASYS[◊]-F Foam Dressing Kit with Soft Port (n=57) or advanced moist wound care of hydrogel dressings, calcium alginate and antimicrobial dressings (n=54) for 16 weeks
 - Most patients received offloading (95%)

Results

- With RENASYS tNPWT compared with advanced moist wound care:
 - More patients had complete DFU closure (64.9 vs 44.4%; p=0.03; Figure)
 - Fewer patients required surgical closure by split thickness skin grafts, flaps, sutures or healed by secondary intention (17.5 vs 55%; p=0.003)
 - Duration of therapy was shorter (12.9 vs 14.9 weeks; p=0.007)
 - Fewer patients required amputation (10.5 vs 25.9%; p=0.03) and there were fewer DFU recurrences (1.8 vs 13.0%; p=0.02)

Conclusions

RENASYS tNPWT is as safe as and more efficacious than conventional advanced moist wound care in the management of DFUs used in a home-care setting

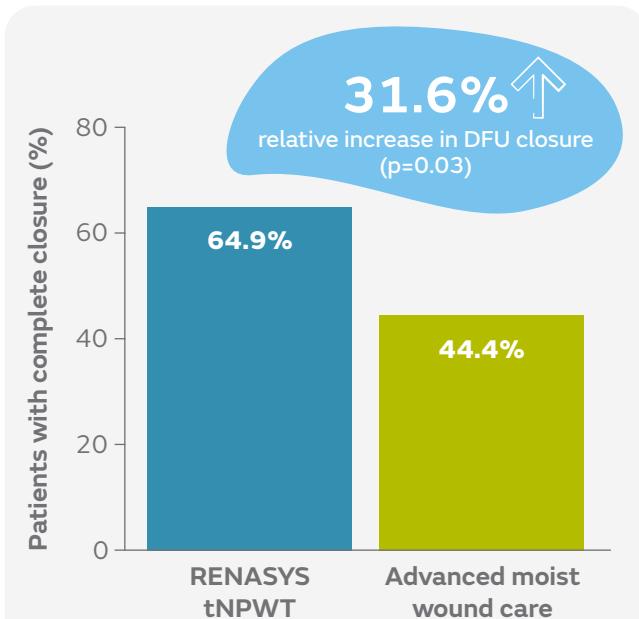


Figure. Patients with complete DFU closure after 16 weeks using RENASYS tNPWT or advanced moist wound care

Fraccalvieri M, et al.



Patient's pain feedback using negative pressure wound therapy with foam and gauze.

Fraccalvieri M, Ruka E, Bocchiotti MA, Zingarelli E, Bruschi S. *Int Wound J.* 2011;8(5):492–499.

Overview

- A single-center, prospective study comparing pain levels before, during and at dressing change with RENASYS[®] tNPWT and V.A.C.[™] NPWT using two different fillers
- Patients with acute trauma wounds received either RENASYS tNPWT with gauze (n=13) or V.A.C.[™] NPWT with foam (n=18)
- Patients responded to a questionnaire about pain levels before, during and at dressing change (0, no pain; 10, worst pain imaginable)

Results

- Mean pain scores were lower with RENASYS tNPWT with gauze than with V.A.C.[™] NPWT with foam)
 - During treatment (3.3 vs 4.3)
 - At dressing change (4.2 vs 6.5; p=0.046; Figure)

Conclusions

Patients reported significantly less pain at dressing change with use of RENASYS tNPWT with gauze versus V.A.C.[™] NPWT with foam

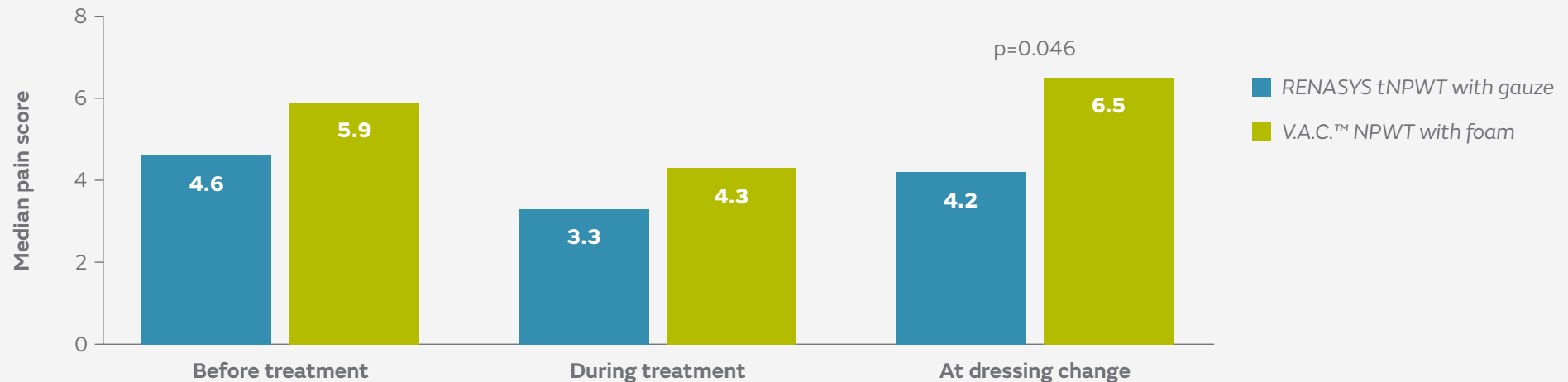
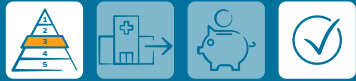

Figure. Mean pain score before treatment, during treatment and during dressing change with RENASYS tNPWT with gauze (n=13) and V.A.C.[™] NPWT with foam (n=18)

Todd J, Somsuk W.



Extensive self-harm scarring: successful treatment with simultaneous use of a single layer skin substitute and split-thickness skin graft.

Todd J, Ud-Din S, Bayat A. *Eplasty*. 2012;12:e23.

Overview

- A retrospective case series of 6 patients with extensive self-harm scarring
- Simultaneous use of a single layer skin substitute and an STSG were combined with immediate application of NPWT with foam filler (RENASYS^o tNPWT or V.A.C.TM NPWT)

Results

- Full wound closure was achieved in all patients within 2 to 4 weeks
- None of the new skin resembled the original scars
- There was variation in the level of pigmentation in the reconstructed area in comparison with native normal skin
- All patients were satisfied with the scars; those with scarring to bilateral arms were keen to proceed with treatment to untreated areas

Conclusions

This surgical treatment option, including use of RENASYS tNPWT with foam, offers an innovative approach to patients with scarring from deliberate self-harm, resulting in aesthetic, psychological, and functional benefits for patients

Ridwan S, et al.



Safety and efficacy of negative pressure wound therapy for deep spinal wound infections after dural exposure, durotomy, or intradural surgery.

Ridwan S, Grote A, Simon M. *World Neurosurg*. 2020 Feb;134:e624–630.

Overview

- A review of 25 patients with dural exposure during primary spinal surgery for deep spinal wound infections (DSWIs) at a single center in Germany
- All patients received NPWT with RENASYS^o-F Foam Dressing Kit with Soft Port

Results

- NPWT was concluded after a median of 4 dressing changes (range, 2 to 14 changes) and 19 days (range, 10 to 70 days); no implant removal was required in any patient

Conclusions

NPWT with RENASYS-F Foam Dressing Kit with Soft Port can be safely applied for deep spinal wound infections after dura exposure or durotomy during the preceding spine surgery

Chipp E, et al.



Extended applications of gauze-based negative pressure wound therapy in hand surgery: A review of five cases.

Chipp E, Sheena Y, Titley O. *J Wound Care*. 2014;23(9):448–451.

Overview

- A series of five cases where RENASYS[®] tNPWT and RENASYS-G Gauze Dressing Kit with Soft Port was used for elective and traumatic wounds of the upper limb at a single-center in the UK

Results

- Using RENASYS tNPWT and RENASYS-G Gauze Dressing Kit simplified dressing regimens, enhanced patient comfort and mobility, and reduced nursing time required for dressings compared with prior practice
- It allowed splinting of hands in the chosen position, stabilization of skin grafts and flaps, and reduced oedema compared with prior practice
- No formal cost-benefit analysis was performed; however, the authors suggested that this approach led to a reduction in interventions (including dressing changes) and facilitated earlier discharge, making RENASYS tNPWT with RENASYS-G Gauze Dressing Kit a cost-effective option compared with prior practice

Conclusions

RENASYS tNPWT and RENASYS-G Gauze Dressing Kit with Soft Port was used successfully in patients with elective and traumatic wounds of the upper limb and was estimated to be cost effective compared with prior practice

Fraccalvieri M, et al.



Treatment of chronic heel osteomyelitis in vasculopathic patients. Can the combined use of Integra[®], skin graft and negative pressure wound therapy be considered a valid therapeutic approach after partial tangential calcaneotomy?

Fraccalvieri M, Pristerà G, Zingarelli E, Ruka E, Bruschi S. *Int Wound J.* 2012;9(2):214–220.

Overview

- A retrospective, single-center study in Italy of seven patients with large ulceration of the heel (>60cm²) managed with partial calcaneotomy, temporary coverage with Integra[™] Dermal Regeneration Template and an STSG
- RENASYS[◇] tNPWT with RENASYS-G Gauze Dressing Kit with Soft Port was used in three patients and V.A.C.[™] NPWT with foam was used in four patients

Results

- After 14 days of NPWT, the superficial silicone outer layer of Integra[™] was removed and an STSG was used to cover regenerated dermis with use of continuous NPWT for 5 days
- All wounds healed with no patient requiring a below-knee amputation (follow up, 13 to 28 months)
- Skin engraftment rates were 100% using RENASYS tNPWT and >90% with Integra[™]; in cases of partial engraftment, wounds healed by secondary intention

Conclusions

Combined use of Integra[™], STSG and NPWT is a valid therapeutic approach for chronic heel osteomyelitis, providing good coverage of bone and complete, lasting wound healing

Bondokji S, et al.



Clinical efficacy of a new variant of a foam-based NPWT system.

Bondokji S, Rangaswamy M, Reuter C, et al. *J Wound Care*. 2011;20(2):62,64–67.

Overview

- A prospective, multi-center study of 18 patients with a range of wound types (pressure ulcers, DFUs, traumatic and surgical wounds) who received V1STA^o tNPWT (prior version of RENASYS^o tNPWT) with RENASYS-F Foam Dressing Kit with Soft Port conducted in Saudi Arabia and the United Arab Emirates

Results

- At the end of therapy, 15 wounds (83%) had progressed sufficiently leading to a change in treatment
- Median reductions in wound area, depth and volume were 31.3%, 45.5% and 74.2%, respectively; weekly reductions were 12.9%, 20.0% and 32.1%, respectively.
- Exudate level ($p=0.013$) and wound malodour ($p=0.03$) significantly reduced compared with the start of NPWT
- Granulation tissue significantly increased ($p<0.001$) and non-viable tissue significantly reduced ($p=0.008$) during NPWT

Conclusions

Use of RENASYS-F Foam Kit produced comparable results to published data on other foam-based NPWT variants

Choi WW, et al.



Negative pressure wound therapy in the management of neonates with complex gastroschisis.

Choi WW, McBride CA, Kimble RM. *Pediatr Surg Int.* 2011;27(8):907–911.

Overview

- Case series (n=4) from a single-center in Australia of neonatal patients with complex gastritis receiving RENASYS[®] tNPWT with RENASYS-G Gauze Dressing Kit with Soft Port to help prevent respiratory embarrassment and/or ACS

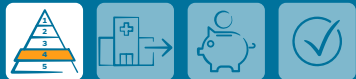Results

- All patients achieved closure of their gastroschisis defects

Conclusions

Use of RENASYS tNPWT with RENASYS-G Gauze Dressing Kit with Soft Port was safe and effective in all four neonates with complex gastroschisis for whom the size of the defect and the condition of the bowel and/or neonate precluded primary closure of the abdomen

Russell F, Jeffery S.



Use of RENASYS Gauze and RENASYS Soft Port to simplify negative pressure dressing techniques.

Russell F, Jeffery S. *Wounds UK.* 2010;6(4):125–130.

Overview

- Two case reports (chronic and trauma wounds) evaluating use of RENASYS EZ tNPWT and RENASYS-G Gauze Dressing Kit with Soft Port compared with prior practice using foam filler at a single centre in the UK

Results

- RENASYS-G Gauze Dressing Kit with Soft Port system reduced the time taken to apply NPWT to wounds and made the application simpler compared with use of foam
- Clinical outcomes in these cases were visible and the authors found an improvement in exudate volume and odour control compared with prior practice using foam

Conclusions

Use of RENASYS-G Gauze Dressing Kit with Soft Port system was simple and effectively delivered NPWT compared with foam filler

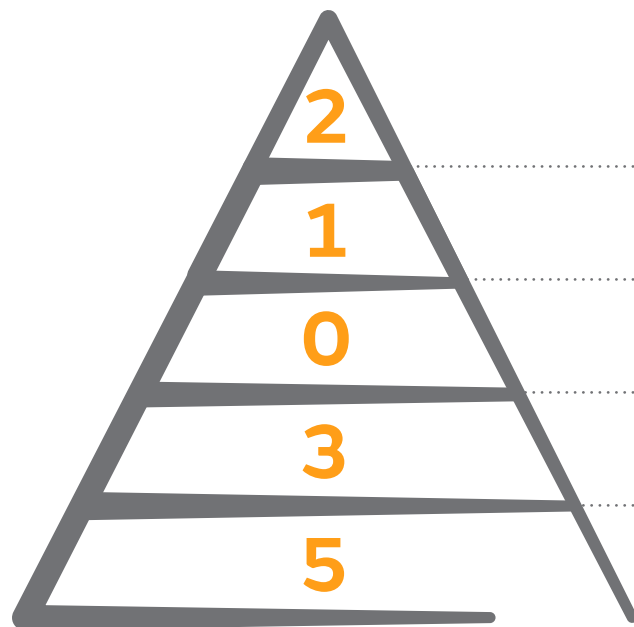
Additional supporting studies

<p>Nagama T, Kakudo N, Kuro A, et al. <i>J Surg Case Rep.</i> 2020;(12):rjaa498.</p>	<p>Full circumference lower extremity degloving injury treated with hydrosurgical debridement and negative-pressure wound therapy with gauze wound filler for fixation of avulsed flap skin grafts.</p>	
<p>Białecki J, Pyda P, Kołodziejska A, Rybak A, Sowier S. <i>NPWT Journal.</i> 2018;5(4):5–8.</p>	<p>Applying NPWT to bleeding open wounds after forefoot amputation in diabetic foot patients—a case report.</p>	
<p>Migacz E, Walczak DA, Maciejewski A, Kukwa W. <i>NPWT Journal.</i> 2018;5(2):14–16.</p>	<p>Successful treatment of postoperative, radiation-associated wound dehiscence around tracheostomy with negative pressure wound therapy.</p>	
<p>Novo-Torres A, Céspedes-Guirao F, Restituyo N, Lorda-Barraguer E. <i>Eur J Plastic Surg.</i> 2016;39(4):297–302.</p>	<p>Management of pyoderma gangrenosum with combination of systemic treatment, vacuum-assisted closure and synthetic dermal substitute.</p>	
<p>Patrut GV, Neamtu C, Ionac M. <i>Int J Surg Case Rep.</i> 2015;16:25–28.</p>	<p>Leg for life? The use of sartorius muscle flap for the treatment of an infected vascular reconstructions after VA-ECMO use. A case report.</p>	
<p>Lavoie MC, Plante M, Lemieux M-C, et al. <i>J Obstet Gynaecol Can.</i> 2014;36(3):253–257.</p>	<p>Extensive adipose tissue necrosis following pfannenstiell incision for endometrial cancer.</p>	
<p>Miura H, Ito Y, Matsuda T, Abe A, Kitaba S. <i>J Cosmetics Dermatological Sciences Applications.</i> 2013;3(01):107–109.</p>	<p>Negative pressure wound therapy with multiple drainage holes for the treatment of pressure ulcer with undermining: case reports.</p>	
<p>Fraccalvieri M, Fierro MT, Salomone M, et al. <i>Int Wound J.</i> 2012;11(2):164–168.</p>	<p>Gauze-based negative pressure wound therapy: a valid method to manage pyoderma gangrenosum.</p>	

Use of RENASYS[◇] Soft Port and drains

This section summarizes key studies evaluating the use of RENASYS Soft Port and drains. The highest levels of evidence available are summarized; therefore, not all studies are included due to volume of publications.

Evidence pyramid



Randomized controlled trials, systematic reviews and meta-analysis

Prospective, observational comparative studies

Retrospective, observational comparative studies

Case series (prospective and retrospective)

Case reports, letters to the editor, expert opinions

Information correct up to 1 March 2021

Angspatt A, et al.



The role of negative-pressure wound therapy in latissimus dorsi flap donor site seroma prevention: a cohort study.

Angspatt A, Laopiyasakul T, Pungrasmi P, Suwajo P. *Arch Plast Surg.* 2017;44(4):308–312.

Overview

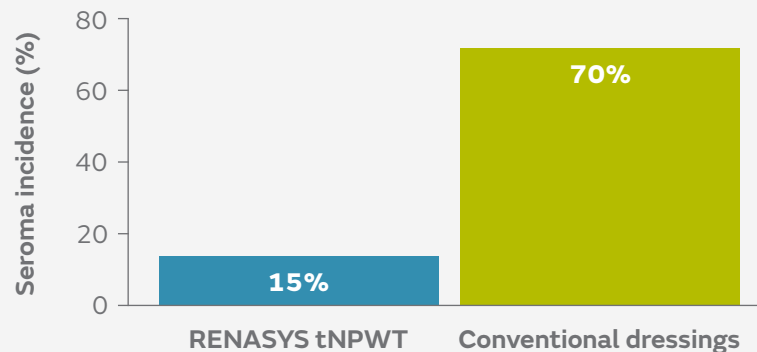
- A prospective, matched-pair study at a single-center in Thailand of 40 patients requiring an LD flap for breast reconstruction
- RENASYS^o tNPWT was used with a drain for 20 patients and a conventional donor site dressing (gauze) was used for a further 20 patients
- Postoperative complications (including seroma incidence and drainage volume) were assessed

Results

- Incidence of seroma after drain removal was lower with RENASYS tNPWT than with conventional dressings (15 vs 70%; Figure)
- Mean percutaneous aspirated volume (26 vs 193ml; p=0.004) and number of percutaneous aspirations (1 vs 3; p=0.001) were significantly lower with RENASYS tNPWT
- Total drainage volume and duration of wound drainage were similar in both groups
- Three patients in the NPWT group had minor skin blisters from the adhesive drape that healed spontaneously with conservative treatment; one patient receiving conventional treatment had an infected seroma

Conclusions

Use of RENASYS tNPWT with a drain helped to reduce the incidence of seroma after removing the drain at the donor site after LD flap harvesting compared with conventional dressings



55% ↓
reduction in seroma incidence
(odds ratio 0.07)

Figure. Seroma incidence with RENASYS tNPWT and conventional dressings

Samir AM, Elewa EA.



Safety and efficacy of negative pressure wound therapy in comparison with advanced moist wound therapy in the treatment of diabetic foot ulcers.

Samir AM, Elewa EA. *Egy J Vasc Endovasc Surg.* 2014;10(3):29.

Overview

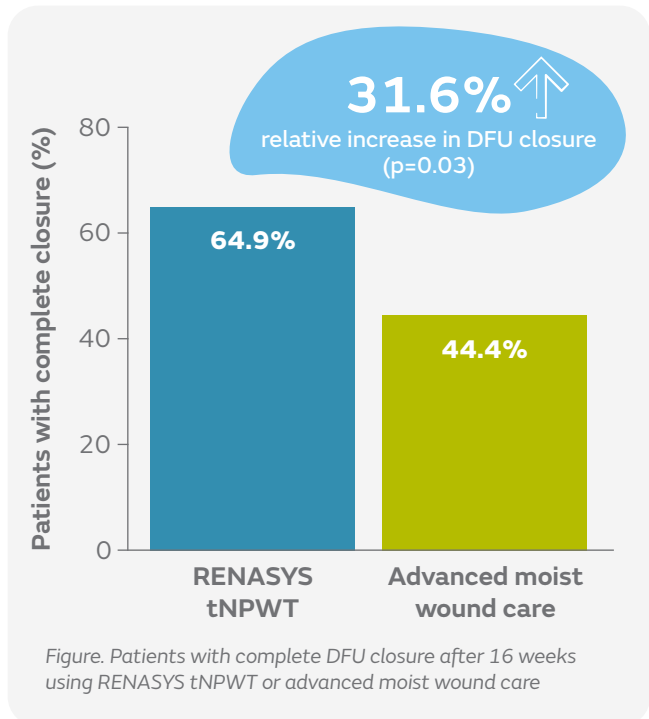
- A randomized, controlled study by a single-center in Egypt comparing the safety and efficacy of RENASYS^o tNPWT with advanced moist wound care for the management of DFUs in the home-care setting
- Patients received either RENASYS tNPWT using RENASYS-F Foam Dressing Kit with Soft Port (n=57) or advanced moist wound care of hydrogel dressings, calcium alginate and antimicrobial dressings (n=54) for 16 weeks
 - Most patients received offloading (95%)

Results

- With RENASYS tNPWT compared with advanced moist wound care:
 - More patients had complete DFU closure (64.9 vs 44.4%; p=0.03; Figure)
 - Fewer patients required surgical closure by split thickness skin grafts, flaps, sutures or healed by secondary intention (17.5 vs 55%; p=0.003)
 - Duration of therapy was shorter (12.9 vs 14.9 weeks; p=0.007)
 - Fewer patients required amputation (10.5 vs 25.9%; p=0.03) and there were fewer DFU recurrences (1.8 vs 13.0%; p=0.02)

Conclusions

RENASYS tNPWT is as safe as and more efficacious than conventional advanced moist wound care in the management of DFUs used in a home-care setting



Schwartz J, et al.



Use of NPWT with and without Soft Port technology in infected foot wounds undergoing partial diabetic foot amputation.

Schwartz J, Fuller A, Avdagic E, Gendics C, Lantis J. *J Wound Care*. 2015;24(Suppl 9):S4–12.

Overview

- A single-center, prospective study in 29 patients with DFUs treated with RENASYS[®] GO tNPWT for 112 days or until primary closure or the wound was ready for delayed primary closure
- Soft Port was used for nine patients

Results

- Seven patients (24%) had delayed primary closure (mean, 58 days) and 52% had sufficient progress to lead to a change in treatment (15/29; mean, 62 days); one DFU had not closed at 112 days
 - Six patients discontinued therapy early (mean, 51 days)
- Median wound area reduced by 39.5% (from 17.4 to 7.6cm²; p=0.001) and there were significant reductions in median wound volume and depth (p<0.001; Figure)
- Estimated time to primary wound closure was 69 days
- Soft Port was well tolerated and effective; time to application was similar for both ports

Conclusions

RENASYS GO tNPWT with and without Soft Port technology were well tolerated and effective when compared with a similar published patient cohort

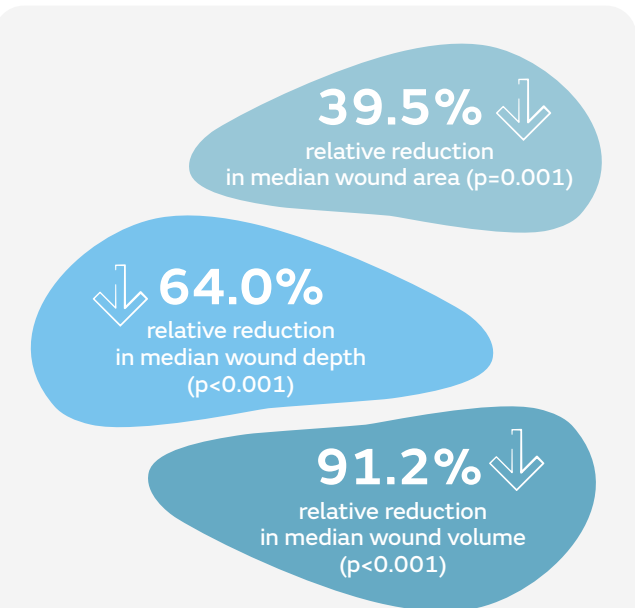


Figure. Changes in wound dimensions from baseline to the end of treatment with RENASYS GO tNPWT

Hattori K, et al.



Temporary vacuum-assisted closure of the open abdomen in neonates.

Hattori K, Numanoglu A, Cox S. *Eur J Pediatr Surg.* 2017;27(5):437–442.

Overview

- A retrospective review of neonates treated with RENASYS[®] EZ PLUS tNPWT with Soft Port and foam filler for open abdomen between 2010 to 2014 at a single centre in South Africa
- A total of 15 neonates received temporary closure for confirmed ACS (n=2) and to help prevent ACS (n=13)






Results

- Duration of RENASYS tNPWT use was 4 ± 3.4 days, during which 2 ± 1.2 applications were performed
- Overall survival rate was 80% (12 of 15 patients)
- One patient with primary ACS died from sepsis with an open abdomen

Conclusions

Use of RENASYS tNPWT with Soft Port on the open abdomen is a safe method of temporary abdominal closure to help prevent ACS in high-risk postoperative conditions in neonates of any gestational age and birth weight

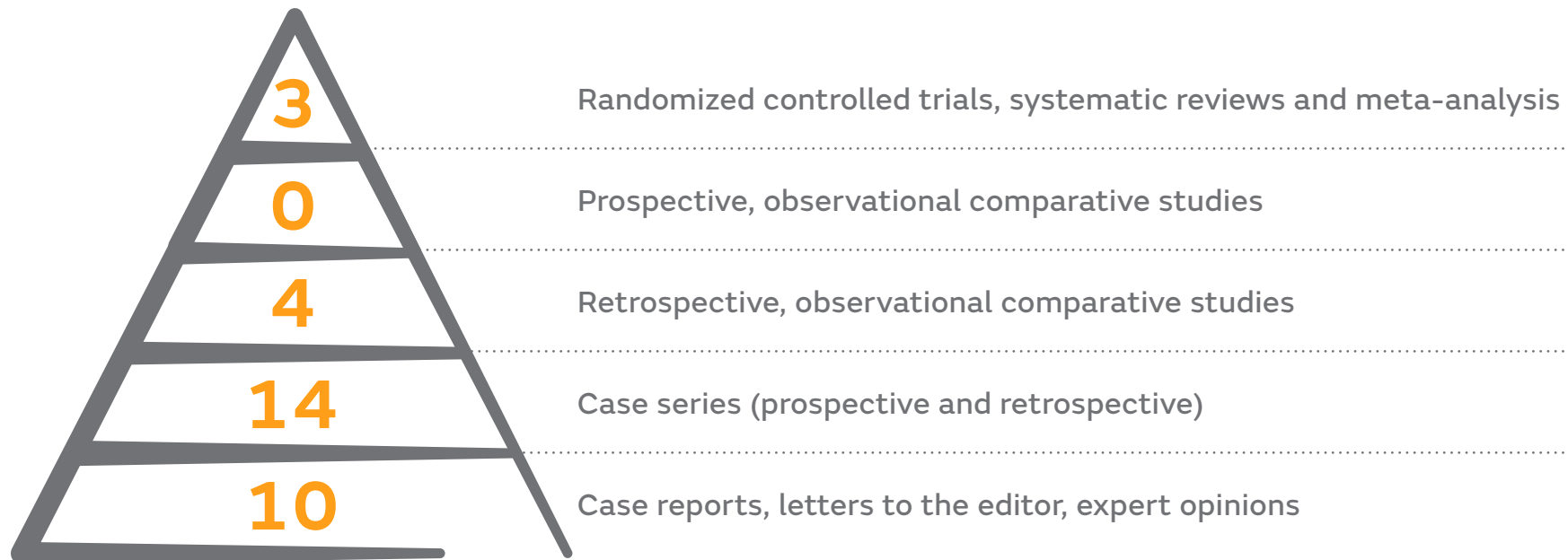Additional supporting studies

<p>Carnali M, Ronchi R, Finocchi L, Meletani T, Capesciotti SS, Paggi B. <i>Acta Vulnologica</i>. 2016;14(1):24–34.</p>	<p>Retrospective study on the use of negative pressure wound therapy in the treatment of pilonidal cysts (sinus pilonidalis) operated on using an open technique or complicated by dehiscence of the surgery site through sepsis.</p>	
<p>Himeno D, Matsuura Y, Maruo A, Ohtori S. <i>J Orthop Sci</i>. 2020 Dec 19:S0949–2658 (20)30350–X.</p>	<p>A novel treatment strategy using continuous local antibiotic perfusion: A case series study of a refractory infection caused by hypervirulent <i>Klebsiella pneumoniae</i>.</p>	
<p>Caputo GG, Marchetti A, Governa M, Dalla Pozza E. <i>J Orthop Trauma</i>. 2019;33(1):e24–e26.</p>	<p>A novel inexpensive technique to seal negative pressure wound therapy on external fixation devices.</p>	
<p>Hirai Y, Yamashita Y, Tazawa H, et al. <i>Gen Thorac Cardiovasc Surg</i>. 2021 Jan 5. [Epub ahead of print]</p>	<p>Negative pressure wound therapy for broncho-pleural fistula with collapsed lung.</p>	
<p>Kage T, Hirota J, Yamamoto N, et al. <i>Int J Surg Case Rep</i>. 2021;78:58–61.</p>	<p>Arthroscopic treatment for Morel-Lavallée lesion of the thigh: A case report and literature review.</p>	
<p>Kitano D, Kitagawa H, Taniguchi T, Sakurai A. <i>Int J Surg Wound Care</i>. 2021;2(1):20–26.</p>	<p>Incisional negative pressure wound therapy with reinforcement of subcutaneous drainage (Hybrid-iNPWT).</p>	
<p>Young CNJ, Ng KYB, Web V, Vidow S, Parasuraman R, Umranikar S. <i>Medicine</i>. 2016;95(50):e5397.</p>	<p>Negative pressure wound therapy aids recovery following surgical debridement due to severe bacterial cellulitis with abdominal abscess post-cesarean: A case report (CARE-Compliant).</p>	
<p>Ogle H. <i>Br J Nurs</i>. 2015;24(Suppl 6):S18–S20.</p>	<p>Drains and gauze-based NPWT in the management of extensive tissue loss.</p>	

Compatibility with other interventions

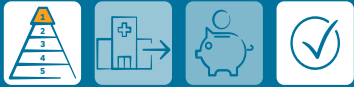This section summarizes key studies evaluating the compatibility of RENASYS[◇] tNPWT with other interventions. The highest levels of evidence available are summarized; therefore, not all studies are included due to volume of publications.

Evidence pyramid



Information correct up to 1 March 2021

Frear CC, et al.



Randomized clinical trial of negative pressure wound therapy as an adjunctive treatment for small-area thermal burns in children.

Frear CC, Cuttle L, McPhail SM, et al. *Br J Surg.* 2020;107(13):1741–1750.

Overview

- A single-center, randomized controlled trial to compare re-epithelialisation of paediatric burns using a combination of ACTICOAT[◇] Antimicrobial Barrier Dressings and Mepitel[™] wound contact layer (standard dressings) with or without adjunctive RENASYS[◇] TOUCH tNPWT
- Children with thermal burns (TBSA <5%) received either standard dressings (n=54) or standard dressings plus RENASYS TOUCH tNPWT (n=47)

Results

- Median time to re-epithelialization was 2 days shorter with RENASYS TOUCH tNPWT than with standard dressings (8 vs 10 days; Figure)
- Use of RENASYS TOUCH tNPWT reduced expected time to wound closure by 22% versus standard dressings (p=0.005)
- Risk of referral to scar management was also reduced by 60% with adjunctive NPWT (5 vs 15 patients; p=0.013)
- Fewer patients in the RENASYS TOUCH group underwent grafting than in the standard dressings group (1 vs 4 patients)
- NPWT was discontinued in four patients (wound maceration, periwound blistering and exacerbation of pre-existing viral illnesses); there were no instances of wound infection

Conclusions

Use of RENASYS TOUCH tNPWT in addition to standard dressings resulted in accelerated re-epithelialization in children with partial-thickness thermal burns and reduced the risk of referral for scar management

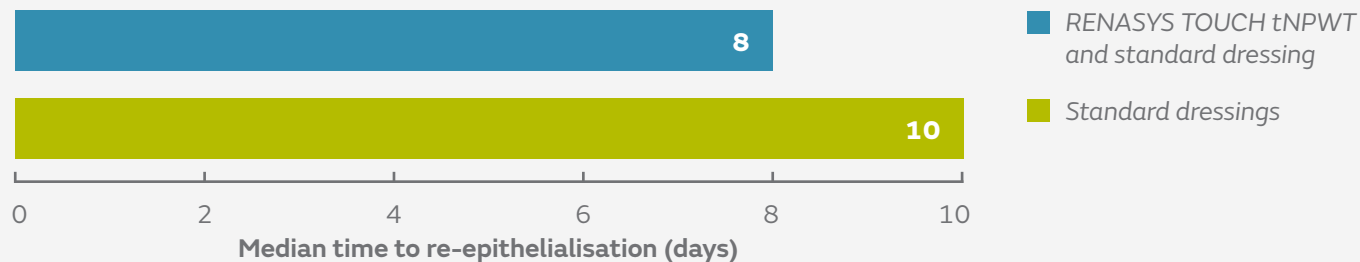


Figure. Median time to re-epithelialisation in paediatric burn patients receiving standard dressings (n=47) and standard dressings plus RENASYS TOUCH tNPWT (n=54)

22% ↓
significant reduction
in time to wound closure
(p=0.005)

Sáez-Martín LC, et al.



Negative pressure and nanocrystalline silver dressings for nonhealing ulcer: A randomized pilot study.

Sáez-Martín LC, García-Martínez L, Román-Curto C, Sánchez-Hernández MV, Suárez-Fernández RM. *Wound Rep Regen.* 2015;23(6):948–952.

Overview

- A prospective, randomized, pilot study to assess RENASYS[◊] GO tNPWT and ACTICOAT[◊] Antimicrobial Barrier Dressings versus RENASYS GO tNPWT alone in the management of chronic wounds at two outpatient clinics in Spain
- Ten patients received the combination treatment and seven patients received RENASYS GO tNPWT alone
- Patients were followed for 6 weeks, with a final assessment at 3 months

Results

- Exudate levels increased to a similar extent throughout the treatment period in both groups
- After 6 weeks, similar amounts of tissue granulation were found in the combination and RENASYS GO tNPWT alone groups (30.0 vs 28.6% of patients)
- Decreases in wound area compared with baseline were similar in both groups
 - In the combination group, there were significant differences versus baseline at week 3 ($p=0.051$) and between weeks 3 and 6 ($p=0.028$)
- No complications or severe adverse events were reported in either group

Conclusions

Use of RENASYS GO tNPWT with ACTICOAT Dressing was safe and as effective as RENASYS tNPWT alone in the management of chronic wounds

Samir AM, Elewa EA.



Safety and efficacy of negative pressure wound therapy in comparison with advanced moist wound therapy in the treatment of diabetic foot ulcers.

Samir AM, Elewa EA. *Egy J Vasc Endovasc Surg.* 2014;10(3):29.

Overview

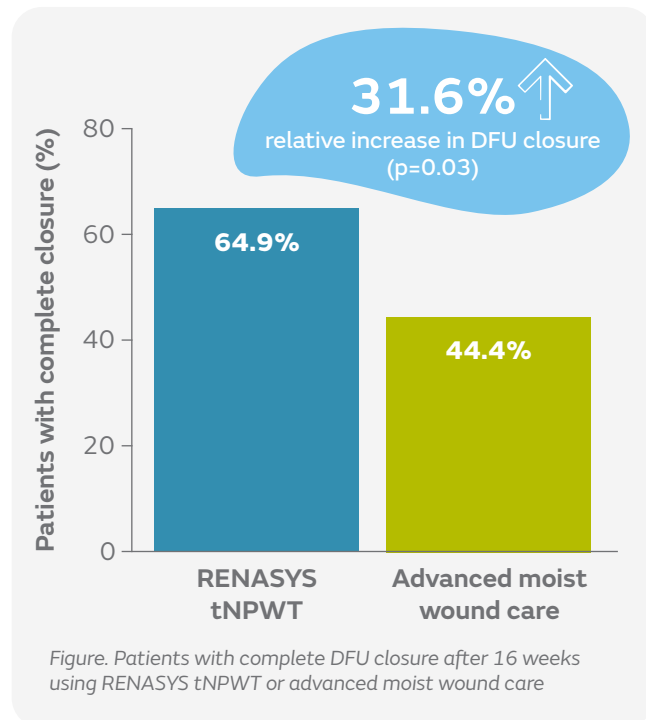
- A randomized, controlled study by a single-center in Egypt comparing the safety and efficacy of RENASYS^o tNPWT with advanced moist wound care for the management of DFUs in a home-care setting
- Patients received either RENASYS tNPWT using RENASYS-F Foam Dressing Kit with Soft Port (n=57) or advanced moist wound care of hydrogel dressings, calcium alginate and antimicrobial dressings (n=54) for 16 weeks
 - Most patients received offloading (95%)

Results

- With RENASYS tNPWT compared with advanced moist wound care:
 - More patients had complete DFU closure (64.9 vs 44.4%; p=0.03; Figure)
 - Fewer patients required surgical closure by split thickness skin grafts, flaps, sutures or healed by secondary intention (17.5 vs 55%; p=0.003)
 - Duration of therapy was shorter (12.9 vs 14.9 weeks; p=0.007)
 - Fewer patients required amputation (10.5 vs 25.9%; p=0.03) and there were fewer DFU recurrences (1.8 vs 13.0%; p=0.02)

Conclusions

When used with offloading devices, RENASYS tNPWT is as safe as and more efficacious than conventional advanced moist wound care in the management of DFUs used in a home-care setting



Nakamura Y, et al.



Negative-pressure closure was superior to tie-over technique for stabilization of split-thickness skin graft in large or muscle-exposing defects: A retrospective study.

Nakamura Y, Fujisawa Y, Ishitsuka Y, et al. *J Dermatol.* 2018;45(10):1207–1210.

Overview

- A retrospective, comparative study of conventional tie-over technique versus NPWT closure for stabilization of STSGs in large or muscle-exposing defects
- Data for 13 patients who underwent STSG for defects in trunk or extremities of >10cm at the longest diameter or with muscle exposure were reviewed
- The tie-over method used bolsters of gauze and gentamicin ointment on the graft, which was fixed with tie-over sutures (n=7)
- In the NPWT group, the graft was fixed with skin staplers, a silicone gauze was placed on the grafts and the RENASYS[®] GO tNPWT canister was bonded with the catheter on the drape (n=6)

Results

- Mean proportion of surviving skin grafts was greater in the RENASYS GO tNPWT group than in the tie-over group (97.9 vs 79.2%; p=0.0012; Figure)
- Mean operative time from harvesting skin grafts until the end of graft stabilization was shorter with RENASYS GO tNPWT than with conventional tie-over (40.3 vs 73.5min; p=ns)

Conclusions

Use of RENASYS GO tNPWT consistently provided ideal graft stabilization on large and muscle-exposing defects and shortened operative time

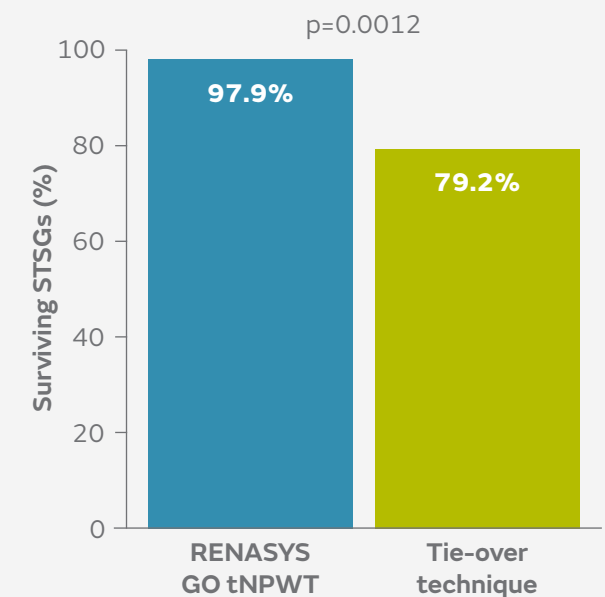
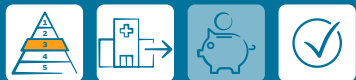

Figure. Proportions of surviving STSGs with use of RENASYS GO tNPWT (n=6) and conventional tie-over technique (n=7)

Hurd T, et al.



A retrospective comparison of the performance of two negative pressure wound therapy systems in the management of wounds of mixed etiology.

Hurd T, Rossington A, Trueman P, Smith J. *Adv Wound Care*. 2017;6(1):33–37.

Overview

- A study comparing clinical outcomes using RENASYS[®] tNPWT with V.A.C.[™] NPWT in a community based setting in Canada
- Patients with a range of wounds (mostly post-surgical wounds) received either RENASYS tNPWT (n=808) or V.A.C.[™] NPWT (n=299)
- For wounds with suspected localized bacterial burden or infection ACTICOAT[®] FLEX 3 Antimicrobial Barrier Dressing was applied according to local protocols (34%)

Results

- Similar numbers of patients achieved treatment goal with RENASYS tNPWT and V.A.C.[™] NPWT (93.6 vs 90.0%)
- Time taken to achieve treatment goal (median 8 weeks in both groups), mean reduction in wound area (65.3 vs 64.2%), and median weekly reduction in wound area (9.7 vs 9.4%) were also similar
- ACTICOAT FLEX 3 Dressing was used successfully as an adjunct to either NPWT system (Figure)

Conclusions

There were no differences in clinical outcomes between RENASYS tNPWT and V.A.C.[™] NPWT (continuous and intermittent use) when used with ACTICOAT FLEX 3 Dressing in patients with a range of wounds treated in a community setting

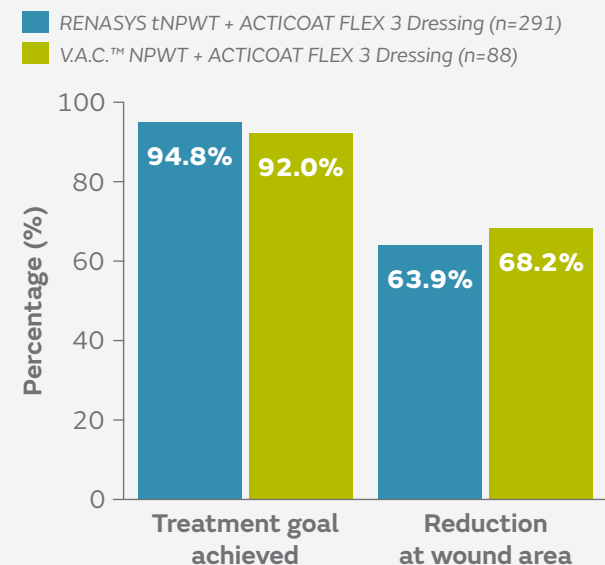
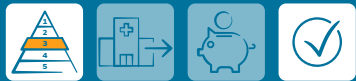

Figure. Proportion of treatment goals achieved and reduction in wound area in patients treated with ACTICOAT FLEX 3 Dressing and RENASYS tNPWT or V.A.C.[™] NPWT

Todd J, Somsuk W.



Extensive self-harm scarring: successful treatment with simultaneous use of a single layer skin substitute and split-thickness skin graft.

Todd J, Ud-Din S, Bayat A. *Eplasty*. 2012;12:e23.

Overview

- A retrospective case series of 6 patients with extensive self-harm scarring
- Simultaneous use of Integra™ single layer skin substitute and an STSG were combined with immediate application of NPWT with foam filler (RENASYS® tNPWT or V.A.C.™ NPWT) for 2 weeks

Results

- Full wound closure was achieved in all patients within 2 to 4 weeks
- None of the new skin resembled the original scars
- There was variation in the level of pigmentation in the reconstructed area in comparison with native normal skin
- All patients were satisfied with the scars; those with scarring to bilateral arms were keen to proceed with treatment to untreated areas

Conclusions

Use of RENASYS tNPWT and foam, with a skin substitute and STSG, offers an innovative approach for patients with scarring from deliberate self-harm, and results in aesthetic, psychological and functional benefits for patients

Hattori K, et al.



Temporary vacuum-assisted closure of the open abdomen in neonates.

Hattori K, Numanoglu A, Cox S. *Eur J Pediatr Surg*. 2017;27(5):437–442.

Overview

- A retrospective review of all neonates treated with RENASYS EZ PLUS tNPWT with Soft Port and foam filler for open abdomen between 2010 to 2014 at a single centre in South Africa
- A total of 15 neonates received temporary closure for confirmed ACS (n=2) and to help prevent ACS (n=13)

Results

- Duration of RENASYS tNPWT use was 4 ± 3.4 days, during which 2 ± 1.2 applications were performed
- Overall survival rate was 80% (12 of 15 patients)
- One patient with primary ACS died from sepsis with an open abdomen







Conclusions

Use of RENASYS tNPWT with foam and a polyvinyl chloride sheet interface on the open abdomen is a safe method of temporary abdominal closure to help prevent ACS in high-risk postoperative conditions in neonates of any gestational age and birth weight

Additional supporting studies

<p>Inukai K, Usui A, Yamada M, et al. <i>Eur J Trauma Emerg Surg.</i> 2021;47(1):93–98.</p>	<p>Open abdominal management for perforative peritonitis with septic shock: a retrospective analysis on usefulness of a standardized treatment protocol.</p>	
<p>Forlee M. <i>Wounds International.</i> 2020. 6 Jan 2020:1–12.</p>	<p>Retrospective chronic and post-surgical wound case series: Understanding RENASYS[®] TOUCH.</p>	
<p>Loh, ML, Goh, BKL, Kong, Y, et al. <i>Int Wound J.</i> 2020;17:1356–1365.</p>	<p>Combination therapy of oxidised regenerated cellulose/collagen/silver dressings with negative pressure wound therapy for coverage of exposed critical structures in complex lower extremity wounds.</p>	
<p>Carnali M, Ronchi R, Finocchi L, Meletani T, Capesciotti SS, Paggi B. <i>Acta Vulnologica.</i> 2016;14(1):24–34.</p>	<p>Retrospective study on the use of negative pressure wound therapy in the treatment of pilonidal cysts (sinus pilonidalis) operated on using an open technique or complicated by dehiscence of the surgery site through sepsis.</p>	
<p>Di Saverio S, Tarasconi A, Inaba K, et al. <i>J Am Coll Surg.</i> 2015;220(3):e23–33.</p>	<p>Open abdomen with concomitant enteroatmospheric fistula: attempt to rationalize the approach to a surgical nightmare and proposal of a clinical algorithm.</p>	
<p>Fox CM, Johnson B, Storey K, Gupta RD, Kimble R. <i>Pediatric Surg Int.</i> 2015;31(7):653–658.</p>	<p>Negative pressure wound therapy in the treatment of ulcerated infantile haemangioma.</p>	
<p>Robin-Lersundi A, Ruiz VV, López-Monclús J, et al. <i>Hernia.</i> 2015;19(2):329–337.</p>	<p>Temporary abdominal closure with polytetrafluoroethylene prosthetic mesh in critically ill non-trauma patients.</p>	
<p>Vaseenon T, Somsuk W. <i>J Med Assoc Thai.</i> 2015;98(1):111–116.</p>	<p>Negative pressure wound therapy for traumatic foot and ankle wound: two case reports and review of the literature.</p>	

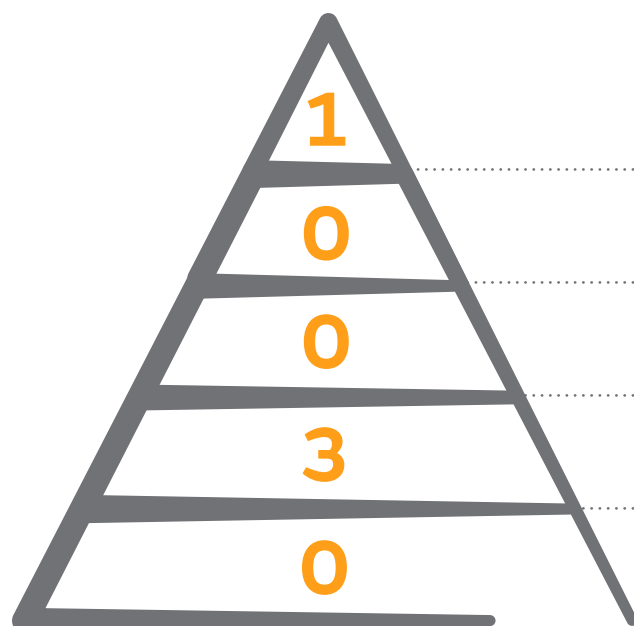
Additional supporting studies

<p>Chipp E, Sheena Y, Titley O. <i>J Wound Care.</i> 2014;23(9):448–451.</p>	<p>Extended applications of gauze-based negative pressure wound therapy in hand surgery: A review of five cases.</p>	
<p>Tian B, Khoo D, Tay AC, et al. <i>Head Neck.</i> 2014;36:873–881.</p>	<p>Management of orocutaneous fistulas using a vacuum-assisted closure system.</p>	
<p>Timmons J, Russell F. <i>Int Wound J.</i> 2014;11(6):723–729.</p>	<p>The use of negative-pressure wound therapy to manage enteroatmospheric fistulae in two patients with large abdominal wounds.</p>	
<p>Fracalvieri M, Pristerà G, Zingarelli E, Ruka E, Bruschi S. <i>Int Wound J.</i> 2012;9(2):214–220.</p>	<p>Treatment of chronic heel osteomyelitis in vasculopathic patients. Can the combined use of Integra®, skin graft and negative pressure wound therapy be considered a valid therapeutic approach after partial tangential calcanectomy?</p>	
<p>Choi WW, McBride CA, Kimble RM. <i>Pediatr Surg Int.</i> 2011;27(8):907–911.</p>	<p>Negative pressure wound therapy in the management of neonates with complex gastroschisis.</p>	
<p>Russell F, Jeffery S. <i>Wounds UK.</i> 2010;6(4):125–130.</p>	<p>Use of RENASYS^o Gauze and Port to simplify negative pressure dressing techniques.</p>	

Ease of use with RENASYS[◇] tNPWT

This section summarizes key studies that evaluated RENASYS tNPWT ease of use. The highest levels of evidence available are summarized; therefore, not all studies are included due to volume of publications.

Evidence pyramid



Randomized controlled trials, systematic reviews and meta-analysis

Prospective, observational comparative studies

Retrospective, observational comparative studies

Case series (prospective and retrospective)

Case reports, letters to the editor, expert opinions

Information correct up to 1 March 2021

Forlee M, et al.



A randomized controlled trial to compare the clinical efficacy and acceptability of adjustable intermittent and continuous Negative Pressure Wound Therapy (NPWT) in a new portable NPWT system.

Forlee M, van Zyl L, Louw H, Nel J, Fourie N, Hartley R. Poster at the EWMA annual meeting, May 9–11, 2018, Krakow, Poland.

Overview

- An open, prospective study conducted in South Africa in patients with acute, sub-acute and chronic wounds that would benefit from NPWT with RENASYS[®] TOUCH tNPWT to achieve adequate wound bed preparation
- Patients received adjustable intermittent (AI; n=35) or continuous therapy (n=36) for 28 days; all settings were determined according to patient need, and choice of wound dressing kit and filler were at the investigator's discretion

Results

- Similar proportions of patients achieved readiness for closure in the AI and continuous therapy groups (42.9 vs 44.4%)
- No pain at dressing removal was reported for 62.7% of assessments for AI therapy and 83.3% for continuous therapy
- No pain at dressing application was reported for 65.3% of assessments for AI therapy and 90.6% for continuous therapy
- Both therapy modes were comfortable to wear at more than 99% of dressing changes
- Clinician acceptability of device functionality was >90% for all parameters assessed using either mode (Figure)

Conclusions

RENASYS TOUCH tNPWT was effective at managing all types of wound using both therapeutic modes with high patient and clinician acceptability

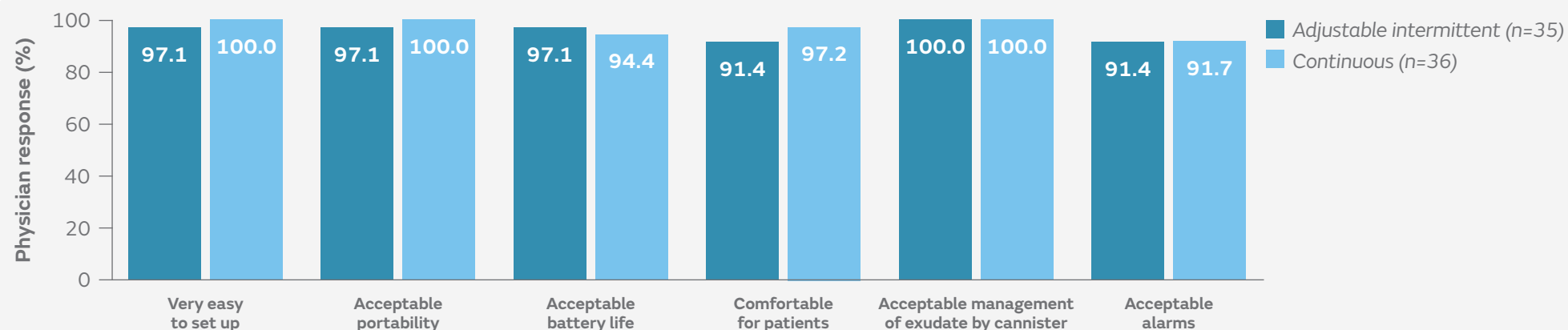
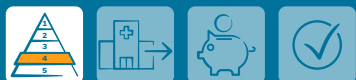

Figure. Clinician ratings of device functionality for RENASYS TOUCH tNPWT with adjustable intermittent and continuous use

Forlee M.

Retrospective chronic and post-surgical wound case series: Understanding RENASYS[◇] TOUCH.

Forlee M. *Wounds International*. 6 Jan 2020:1–12.

Overview

- A series of eight patient cases treated with RENASYS TOUCH tNPWT as part of an open-label, multi-center, randomized controlled trial conducted in South Africa
- Two cases required intermittent use of RENASYS TOUCH tNPWT to help manage pain and infection, respectively; other cases used continuous therapy

Results

- **Patient 1** – adjusting the continuous pressure rate down helped the patient to feel the dressing was comfortable
- **Patient 2** – the device was judged by the patient to be comfortable; it was gentle on fragile and previously damaged periwound skin
- **Patient 3** – ability to adapt NPWT increased clinician options to improve patient tolerability

Conclusions

The ability to adapt therapy with RENASYS TOUCH tNPWT gave the clinician options with regard to patient tolerability of NPWT

Fox CM, et al.



Negative pressure wound therapy in the treatment of ulcerated infantile haemangioma.

Fox CM, Johnson B, Storey K, Gupta RD, Kimble R. *Pediatric Surg Int*. 2015;31(7):653–658.

Overview

- Six consecutive paediatric patients with ulcerating infantile haemangioma were treated using RENASYS GO tNPWT (with gauze filler) and propranolol (1mg/kg/day) at a single-center in Australia
- ACTICOAT[◇] Antimicrobial Barrier Dressing was also applied

Results

- Complete wound healing was achieved for all patients
- Patient outcomes in terms of analgesia, comfort, and ease of wound dressing management were improved following application of NPWT compared with standard dressings (propranolol, emollients and non-adhesive dressings)

Conclusions

Use of RENASYS GO tNPWT with propranolol in patients with ulcerating infantile haemangioma improved ease of wound dressing management compared with prior daily dressing changes

Moffatt C, et al.



The experience of patients with complex wounds and the use of NPWT in a home-care setting.

Moffatt C, Mapplebeck L, Murray S, Morgan P. *J Wound Care*. 2011;20(11):512-527.

Overview

- A study to evaluate the impact of using RENASYS GO tNPWT in a home-care setting
- Patients (n=8) with complex wounds who had received at least 10 days of NPWT were recruited from a tissue viability service in the UK

Results

- Half of patients achieved wound closure within 2 months
- Patients evaluated RENASYS GO tNPWT as comfortable, light and quite easy to use
- Two patients had been previously treated with V.A.C.™ NPWT and said that RENASYS GO tNPWT was lighter and less noisy, particularly at night

Conclusions

RENASYS GO tNPWT, in the home-care setting, was comfortable for patients with complex wounds, and was lighter and less noisy than V.A.C.™ NPWT for some patients

Developed by Evidence Communications, Global Clinical
& Medical Affairs

www.smith-nephew.com/education

For detailed product information, including indications for use, contraindications, precautions and warnings, please consult the product's applicable Instructions for Use (IFU) prior to use.

Advanced Wound Management
Smith & Nephew
Fort Worth, TX 76109 USA
T +1 (800) 876 1261
F +1 (727) 392 6914

www.smith-nephew.com/usrenasys

◇ Trademark of Smith+Nephew
All Trademarks acknowledged
©June 2021 Smith+Nephew

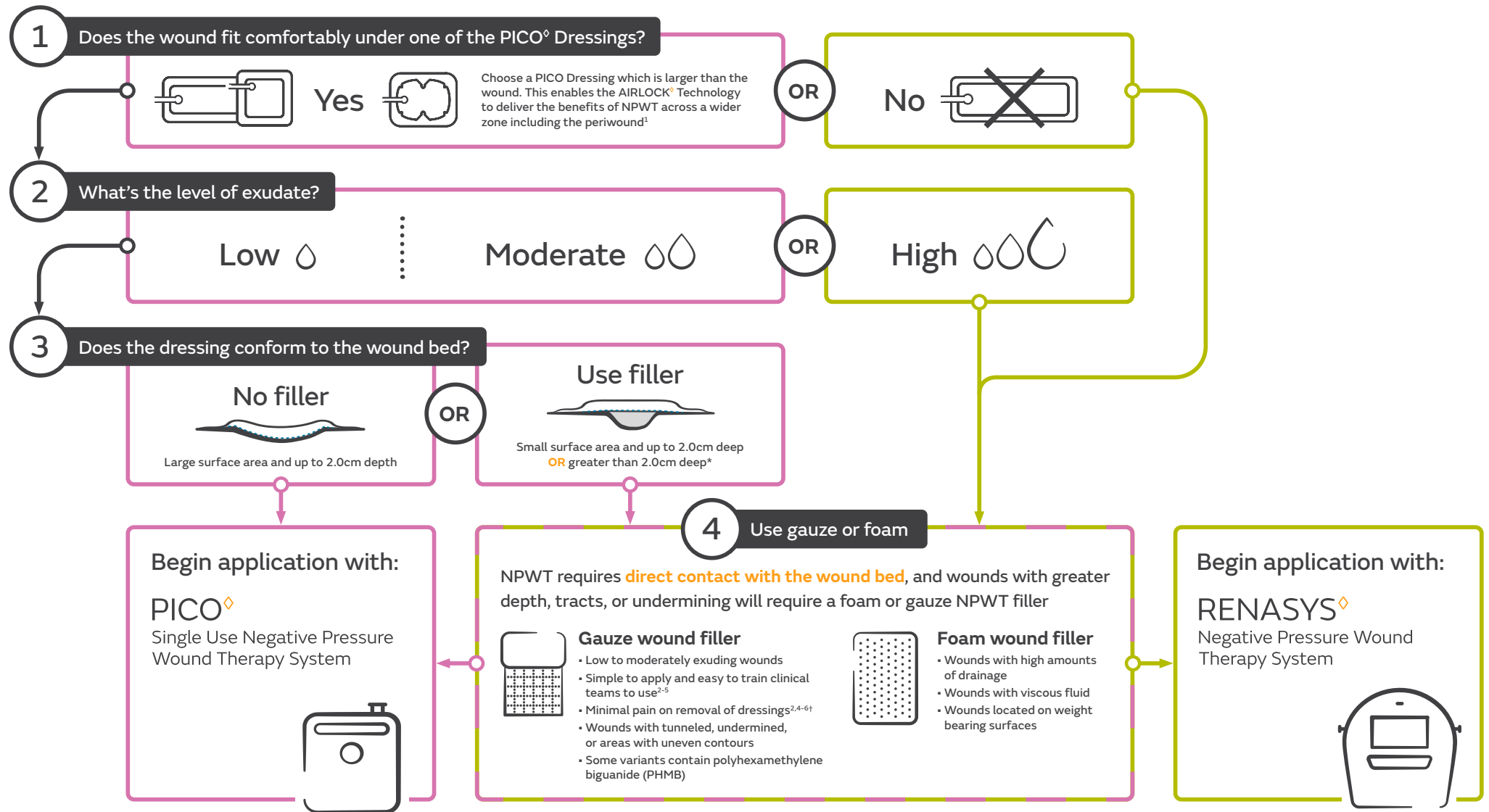
30046_US

Smith+Nephew

References:

1. Rahmanian-Schwarz A, Willkomm L-M, Gonser P, Hirt B, Schaller H-E. A novel option in negative pressure wound therapy (NPWT) for chronic and acute wound care. *Burns*. 2012;38(4):573–577.
2. Hurd T, Rossington A, Trueman P, Smith J. A retrospective comparison of the performance of two negative pressure wound therapy systems in the management of wounds of mixed etiology. *Adv Wound Care*. 2017;6(1):33–37.
3. Forlee M, Nel J, Richaron J, Rossington A, Cockwill J, Smith J. An interim analysis of device functionality and usability of RENASYS TOUCH - a new portable Negative Pressure Wound Therapy (NPWT) system. Poster presented at Wounds UK, November 14–16, 2016, Harrogate, UK.
4. Forlee M, van Zyl L, Louw H, Nel J, Fourie N, Hartley R. A randomised controlled trial to compare the clinical efficacy and acceptability of adjustable intermittent and continuous Negative Pressure Wound Therapy (NPWT) in a new portable NPWT system. Poster presented at the EWMA annual meeting, May 9–11, 2018, Krakow, Poland.
5. Hudson D, Adams K, Cockwill J, Smith J. Evaluation of a new Negative Pressure Wound Therapy (NPWT) suction port (RENASYS Soft Port). Poster presented at the EWMA annual meeting, May 15–17, 2013, Copenhagen, Denmark.
6. Carnali M, Ronchi R, Finocchi L, Meletani T, Capesciotti SS, Paggi B. Retrospective study on the use of negative pressure wound therapy in the treatment of pilonidal cysts (sinus pilonidalis) operated on using an open technique or complicated by dehiscence of the surgery site through sepsis. *Acta Vulnologica*. 2016;14(1):24–34.
7. Apelqvist J, Willy C, Fagerdahl AM, et al. Negative pressure wound therapy – overview, challenges and perspectives. *J Wound Care*. 2017;26:3(Suppl 3):S1–S113.
8. McKanna M, Geraci J, Hall K, et al. Clinician panel recommendations for use of negative pressure wound therapy with instillation. *Ostomy Wound Manage*. 2016;62(4):S1–S14.
9. Kim PJ, Attinger CE, Constantine T, et al. Negative pressure wound therapy with instillation: International consensus guidelines update. *Int Wound J*. 2020;17(1):174–186.
10. National Institute for Health and Care Excellence. Medtech Innovation Briefing 189. The V.A.C.[™] Veraflo Therapy system for infected wounds. 2 Sep 2019. Available at: <https://www.nice.org.uk/advice/mib189>. Accessed 05 Aug 2020.
11. Gupta S, Gabriel A, Lantis J, Téot L. Clinical recommendations and practical guide for negative pressure wound therapy with instillation. *Int Wound J*. 2016;13(2):159–174.
12. Anghel EL, Kim PJ. Negative-pressure wound therapy: A comprehensive review of the evidence. *Plast Reconstr Surg*. 2016;138(3 Suppl):1295–375. (Abstract only).
13. Kirsner RS, Hurd T. Assessing the need for negative pressure wound therapy utilization guidelines: an overview of the challenges with providing optimal care. *Wounds*. 2020;32(12):328–333.
14. Hurd T, Kirsner RS, Sancho-Insenser JJ, et al. International consensus panel recommendations for the optimization of traditional and single-use negative pressure wound therapy in the treatment of acute and chronic wounds. *Wounds*. 2021;33(suppl 2):S1–S11.

+ OneNPWT clinical decision tree for open wounds



Smith+Nephew does not provide medical advice. The information presented is not, and is not intended to serve as, medical advice. It is the responsibility of healthcare professionals to determine and utilize the appropriate products and techniques according to their own clinical judgment for each of their patients. The information presented may not be appropriate for all jurisdictions. For detailed product information, including indications for use, contraindications, precautions and warnings, please consult the product's applicable Instructions for Use (IFU) prior to use.

* Wounds must not contain exposed arteries, veins, nerves or organs. † p=0.046; n=31: Compared to black foam in acute post traumatic wounds. **Reference:** 1. Brownhill R. PICO[◇] Biomechanical Study. Data on file report. August 2019. DS/19/211/R. 2. Hurd T, Chadwick P, Cote J, Cockwill J, Mole T, Smith J. Impact of gauze-based NPWT on the patient and nursing experience in the treatment of challenging wounds. International Wound Journal. 2010;7(6):448-455. 3. Fracalvieri M, Scalise A, Ruka E, et al. Negative pressure wound therapy using gauze and foam: Histological, immunohistochemical, and ultrasonography morphological analysis of granulation and scar tissues – Second phase of a clinical study. In: European Journal of Plastic Surgery. Vol 37 2014:411-416. 4. Johnson S. V1STA[®] – A new option in Negative Pressure Therapy. Journal of Wound Technology. 2008;1:30-31. 5. Fracalvieri M, Ruka E, Bocchiotti M, Zingarelli E, Bruschi S. Patient's pain feedback using negative pressure wound therapy with foam and gauze. International wound journal. 2011;8(5):492-499. 6. Smith+Nephew 2009. A prospective, open labelled, multicentre evaluation of the use of VISTA in the management of chronic and surgical wounds and A prospective, open labelled evaluation of the use of EZCare in the management of chronic and acute wounds. Internal Report. SR/CIME/010/012. [◇]Trademark of Smith+Nephew. All Trademarks acknowledged. ©November 2020 Smith+Nephew. AWM-AWD-28344 | GMC1146d | RoW