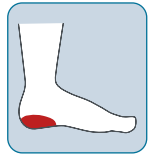

RENASYS[◇] EDGE System utilized to treat non-healing pressure injury wound with history of infection and osteomyelitis in the lower limb

Presentation

A 43-year-old male with multiple comorbidities, including limited mobility, developed an unstageable pressure injury (PI) on the right heel. Wound was non-healing with a history of infection, unsuccessful antibiotic treatment, and osteomyelitis development. Treatment was delivered at patient's place of residence, a long-term care facility.



Treatment

- Wound care specialist were involved 4 weeks post-PI development, wound documented as non-healing with presence of infection
- Initial treatment included regular sharp debridement, antibiotics and alternative traditional negative pressure wound therapy (tNPWT)
- Patient developed several infections, leading to hospitalization due to osteomyelitis, and subsequent long-term antibiotic treatment
- Decision was made by HCPs to switch treatment to RENASYS EDGE tNPWT with foam filler
 - Continuous tNPWT treatment, dressing changed Tuesdays and Fridays
- Following clinical improvement, including reduction in wound size and exudate levels, treatment was stepped down to PICO[◇] single use negative pressure wound therapy (sNPWT)

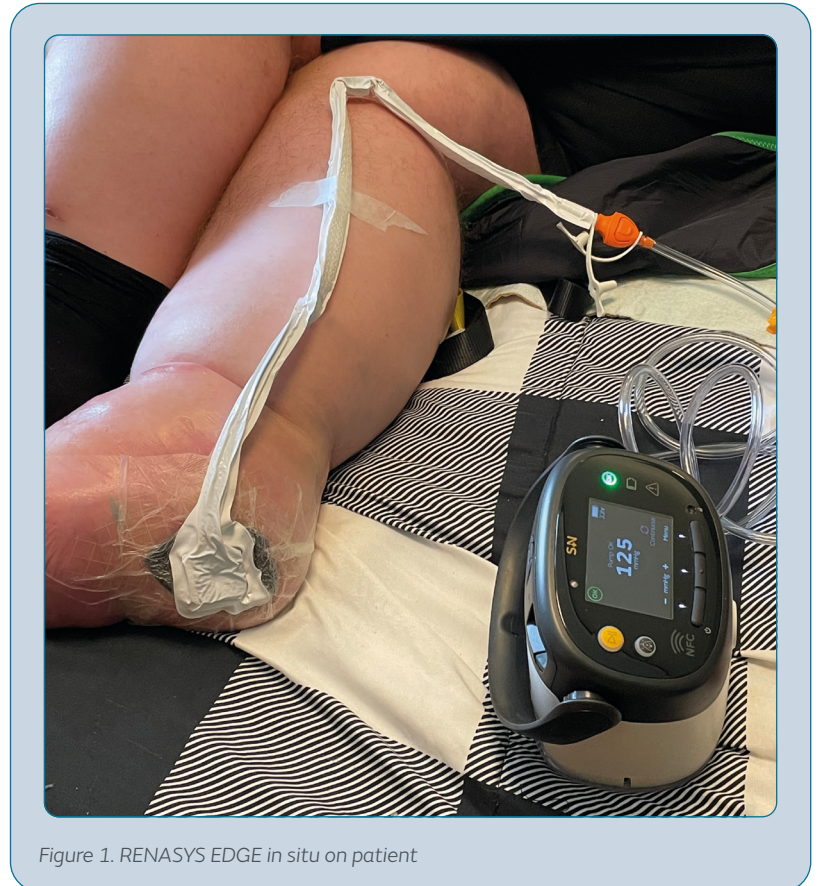

Figure 1. RENASYS EDGE in situ on patient

Outcomes



Patient comfort and **quality of life maintained** during therapy with RENASYS EDGE tNPWT



HCPs found RENASYS EDGE tNPWT **user-friendly**



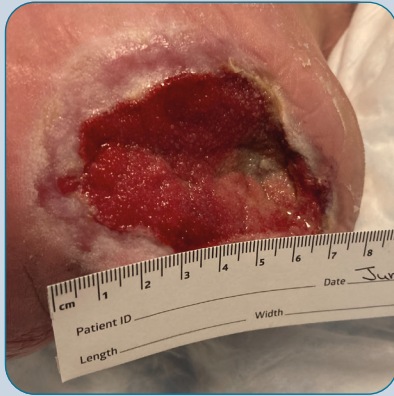Wound **progressed towards healing**, allowing step down to sNPWT when clinically appropriate

Assessment



Day 0

Prior to initiating treatment with RENASYS[®] EDGE tNPWT



Wound bed 95% granulation tissue and 5% adipose tissue.

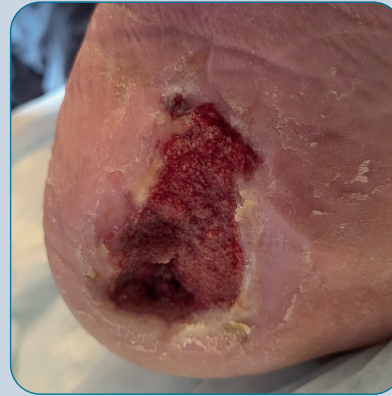LWD: 7.0 x 5.2 x 1.4cm

Figure 2



~3 weeks

after initiating treatment with RENASYS EDGE tNPWT



Wound bed 100% granulation tissue.

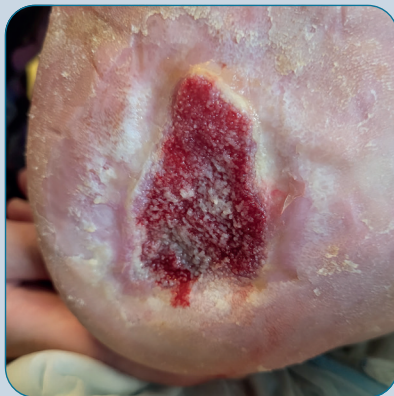LWD: 6.0 x 3.5 x 1.0cm

Figure 3



~8 weeks

after initiating treatment with RENASYS EDGE tNPWT



Healthy granulation tissue with increased epithelialization evident.

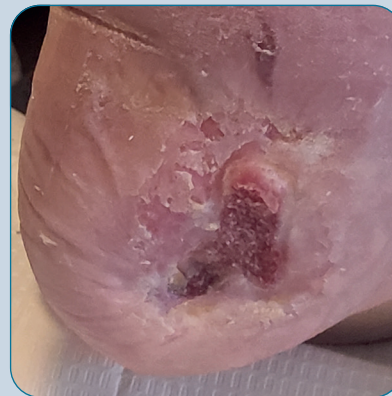
LWD: 4.8 x 3.2 x 0.5cm

Figure 4



~10 weeks

after initiating treatment with RENASYS EDGE tNPWT



Substantial contraction and reduction in size, wound-bed clean and granulating. Treatment with RENASYS EDGE System stopped and PICO[®] sNPWT initiated.

Figure 5

Summary

RENASYS EDGE System utilized in the treatment of a non-healing PI, achieving successful healing outcomes in line with pre-specified treatment goals and maintenance to the patients quality of life.

This case is provided for informational and educational purposes only. This case may not represent typical outcomes. Every procedure and each patient undergoing wound treatment represents unique sets of circumstances and, therefore, results may vary. Smith+Nephew does not provide medical advice. The information presented is not, and is not intended to serve as, medical advice. It is the responsibility of the treating physician to determine and utilize the appropriate products and techniques according to their own clinical judgment for each of their patients.

For detailed product information, including indications for use, contraindications, precautions and warnings, please consult the product's applicable Instructions for Use (IFU) prior to use.

Acknowledgements: Images used with permission from Patricia L Kearney, CEO & Administrator, Tidal View Manor, Nova Scotia, Canada.

This real-world data was collected and provided by Global Clinical Strategy.