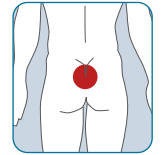


RENASYS[®] EDGE Traditional Negative Pressure Wound Therapy (tNPWT) System utilized to treat a cavity wound that originated as moisture associated skin damage (MASD) to buttocks

Presentation

A 59-year-old male suffered a cerebrovascular accident, resulting in paraplegia and wheelchair-dependence. The patient suffered with ongoing incontinence that created severe MASD, eventually manifesting as a cavity wound. Treatment was delivered at the patient's place of residence, a long-term care facility.

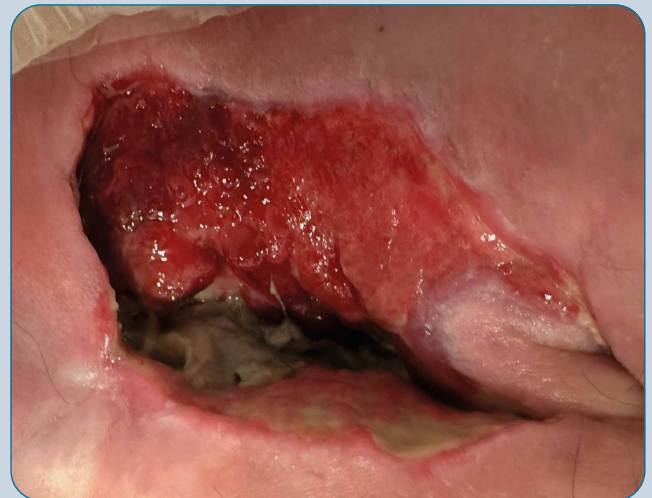

Treatment

- Initial treatment included pressure relief, optimal skin care and nutritional protein supplement
 - Wound packed with antibacterial dressing, non-sting skin prep applied to peri-wound area, covered with a foam dressing and changed 3x weekly
- Wound healing impeded due to patient non-compliance with pressure area care and repositioning regimes
 - Patient spent extended periods of time in their wheelchair that did not adhere to the recommended/optimal pressure redistribution plan
- The wound management team, including patient and family through shared decision making (SDM) wanted the resident to enjoy life while still managing the wound and promoting healing
- Decision was made to switch treatment to RENASYS EDGE tNPWT with foam filler, alongside continuation of skin care and pressure relief
 - Dressing changed 3x weekly due to requirement of bowel stimulation and evacuation
 - Wound present for ~23 weeks at time of initiation with RENASYS EDGE tNPWT



Prior to initiating treatment with RENASYS EDGE tNPWT



LWD:
7.0 x 6.0 x 5.0cm

Figure 1

Outcomes



RENASYS EDGE tNPWT allowed the patient to **continue daily activities** while **managing the wound and promoting healing**

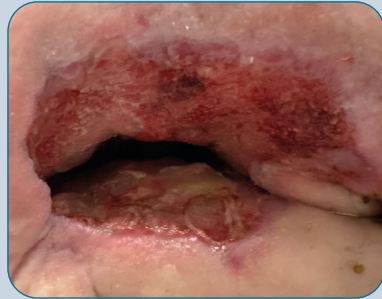


The wound **progressed towards healing**, after initiation of RENASYS EDGE tNPWT despite compromised pressure area care

Assessment



After initiating treatment with RENASYS[®] EDGE tNPWT



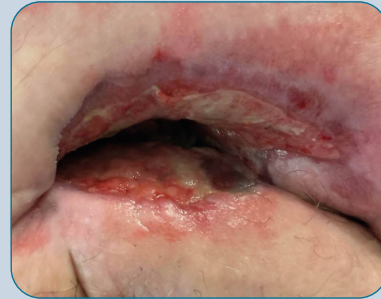Tunneling of 1cm noted and being managed by the care team.
Fast and effective results seen after 1 week, treatment with RENASYS EDGE tNPWT continued.

LWD:
5.0 x 3.3 x 4.0cm

Figure 2



After initiating treatment with RENASYS EDGE tNPWT



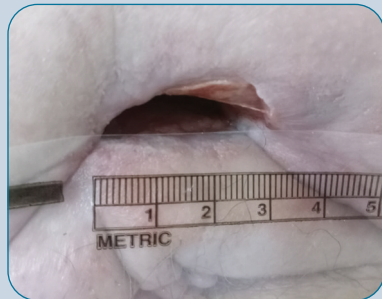Contraction of wound and reduction in size.
Tunneling resolved and exudate being managed effectively.

LWD:
5.0 x 3.0 x 3.0cm

Figure 3



After initiating treatment with RENASYS EDGE tNPWT



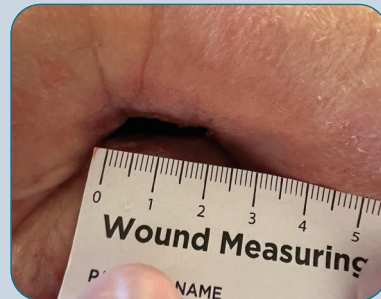
Substantial contraction of wound and reduction in size.

LWD:
3.0 x 1.0 x 2.0cm

Figure 4



After initiating treatment with RENASYS EDGE tNPWT



Healing continued and further reduction of wound size observed.

LWD:
2.0 x 0.7 x 2.0cm

Figure 5

Summary

RENASYS EDGE tNPWT System utilized in the treatment of a MASD-induced cavity wound, achieving successful healing outcomes in line with pre-specified SDM treatment goals and maintenance to the patients quality of life.

This case is provided for informational and educational purposes only. This case may not represent typical outcomes. Every procedure and each patient undergoing wound treatment represents unique sets of circumstances and, therefore, results may vary. Smith+Nephew does not provide medical advice. The information presented is not, and is not intended to serve as, medical advice. It is the responsibility of the treating physician to determine and utilise the appropriate products and techniques according to their own clinical judgment for each of their patients.

For detailed product information, including indications for use, contraindications, precautions and warnings, please consult the product's applicable Instructions for Use (IFU) prior to use.

Acknowledgements: Images used with permission from Michael Douglas Galera, Director of Care, Cedarstone Enhanced Care, Nova Scotia, Canada.

Advanced Wound Management
Smith & Nephew, Inc.
Fort Worth, TX 76109 USA

T 800-876-1261
F 727-392-6914
www.smith-nephew.com

[®]Trademark of Smith+Nephew
All Trademarks acknowledged
©2024 Smith+Nephew
RNCE10-42081-0324